

DISCHARGE PATTERNS OF THE SPASM ACTIVITY IN HEMIFACIAL SPASM: A SUMMARY OF 206 PATIENTS

Meral Erdemir Kızıltan Prof. MD, Rağsan Şahin MD, Mehmet Ali Akalın Assoc. Prof. MD, Nurten Uzun Assoc. Prof. MD, Feray Karaali Savrun, Assoc. Prof. MD

Istanbul University, Cerrahpasa Medical Faculty, Department of Neurology, Istanbul, Turkey

ABSTRACT

• **Objective:** We have summarized the electrophysiological recordings of 206 patients with hemifacial spasm (HFS).

• **Material and Method:** The clinical and electrophysiological data of 206 patients with primary HFS followed between 1992- 2004 in our department were included. Electrically elicited blink reflex responses and discharge patterns of spasm activities recorded by surface electrodes and their correlation with clinical features of the patients were evaluated.

• **Results:** The mean age of the patients was 51.4 years. While, 105 patients' spasms were in left side, three patients's were bilateral. R_1 and R_2 latencies did not differ between

both in spasm and unaffected sides. Discharge patterns of the spasm activities were grouped as single isolated, clustered and tonic spasm. Isolated discharges were more prevalent in patients with less disease duration.

As the disease duration increases, they tend to be displaced by tonic spasms. More than one kind of activity could be seen in the same patient, 18 patients had all kind.

• **Conclusion:** Electromyographic appearance of spasm activity is not uniform in cases with HFS and it may change parallel to the disease duration.

• **Key Words:** Hemifacial spasm, surface EMG, spasm activity, electrophysiological findings. *Nobel Med 2010; 6(2): 9-14*

HEMİFASİYAL SPAZMDA SPAZM AKTİVİTESİNİN DEŞARJ PATERNLERİ: 206 HASTANIN İNCELENMESİ

ÖZET

- **Amaç:** Hemifasiyal spazmı olan 206 hastanın elektrofizyolojik bulgularının değerlendirilmesi amaçlandı.
- **Materyal ve Metod:** Kliniğimizde 1992-2004 yılları arasında primer hemifasiyal spazmı olan 206 hastanın klinik ve elektrofizyolojik verileri çalışmaya alınmıştır.
- **Bulgular:** Hastaların ortalama yaşı 51,4 idi. 105 hastanın spazmı sol tarafta iken, 3 hastanın iki taraflı

idi. R₁ ve R₂ latensleri spazm olan taraf ile sağlam taraf arasında değişiklik göstermiyordu. Spazm aktivitesinin deşarj paternleri tek izole, gruplar halinde ve tonik spazm olarak ayrıldı. Hastalık süresi kısa olanlarda izole deşarjlara daha sık rastlanıyordu. Hastalık süresinin uzaması ile yerlerini tonik spazma bırakma eğilimi görülmüyordu. Bir hastada birden fazla aktivite görülebiliyordu. 18 hastada tüm aktiviteler vardı.

• **Sonuç:** HFS olan hastalarda spazm aktivitesinin elektro-miyografik görünümü uniform değildi ve hastalığın süresine göre değişiklikler gösteriyordu.

• **Anahtar Kelimeler:** Hemifasiyal spazm, yüzey EMG, spazm aktivitesi, elektrofizyolojik bulgular **Nobel Med 2010; 6(2): 9-14**

INTRODUCTION

Hemifacial spasm (HFS) is a disorder that usually begins in adulthood and is characterized by involuntary tonic or clonic contractions or twitches on one side of the face. It is believed that spasms appear first around the orbicularis oculi, than affect lower parts of face. Beside the spasms, synkinetic co-contraction of muscles receiving innervations from different branches of the facial nerve is a well-known characteristic of HFS. Compression of the facial nerve at the root exit zone with vascular loop is widely accepted as a causative hypothesis.^{1,2}

The electrophysiological features of HFS are well known entity. However, the discharge pattern of the spasm activity has not gained too much interest. Firing pattern varies with short bursts of one or few motor units, lasting from 10 to 100 ms or prolonged spasms of several synchronized motor units lasting some seconds.³ The second form of spontaneous activity is a long-lasting slow contraction. Electromyographic (EMG) examination shows slower contraction pattern resembling interference pattern seen upon normal voluntary contraction.^{4,5}

Discharge patterns of the spasm activities are grouped as isolated single, clustered rapid burst, and tonic spasm based on the electrophysiological appearance. Isolated single discharges consist of brief, irregular firing of single units.⁶ Clustered rapid bursts (rapid twitch pattern and blink bursts) are composed of sudden-onset high frequency bursts (>200 c/sec) made up of 2 to 40 potentials. Some of this kind of activity is associated with the eye blink. Tonic spasms (slower contraction pattern) are similar to those of full interference pattern was the first type of tonic spasm.

The second pattern of tonic spasm consisted of consecutive and very close burst or single discharges, which persist for several seconds.⁷

In this study, we present the electrophysiological features of HFS patients studied in our EMG department. A polymyographic surface EMG (SEMG) was used to study the voluntary and involuntary movements in patients with HFS. The aim of this study was to document the characteristics of the discharge patterns of spasms and synkinetic co-activation in patients with different symptom duration. In addition, the blink reflexes (BR) of all patients were studied to determine the synkinetic distribution in the lower facial muscles.

MATERIAL and METHOD

The electrophysiological data of 206 patients, 87 of whom were men, with primary HFS followed between 1992 and 2004 were included in the study. Their ages ranged from 18-82 years (mean 51.4 years). None of the patients had received Botulinum toxin treatment prior to electrophysiological examination. All patients underwent electrodiagnostic testing, which included BR and surface recordings of voluntary and involuntary muscle activity. All cases were evaluated according to the electrophysiological and clinical findings. All subjects gave written informed consent and the local ethics committee approved the study.

All tests were performed at the supine position. BR and EMG activity were recorded using bipolar Ag-AgCl surface electrodes. The electrodes were placed over the lower portion of orbicularis oculi muscle on both sides, and over the orbicularis oris muscle on the symptomatic side. Four channels Dantec Counterpoint Mk 2 (Denmark) and eight channels→

Nihon Kohden Neuropack Σ (Japan) EMG devices were used. BRs were obtained by percutaneous electrical stimulation of supraorbital nerve on the same electrode position. The cathode was placed over the supraorbital notch, and anode was placed 2 cm superiorly. Electric shocks lasted 0.2 ms and 3 times the first R_2 threshold. The ground electrode was placed over the upper part of the sternum. Electrical stimuli were given at irregular intervals during the spasm free periods. Upper and lower frequency bands were chosen as 1 KHz and 20Hz. Input sensitivity was adjusted as 100-200 μ V. Onset latencies of initial deflections of early and late responses were measured. Latencies of R_1 responses longer than 13 ms and R_2 responses longer than 41 ms are considered as abnormal. BR latencies were compared both spasm and unaffected sides. For the side-to-side comparisons, the difference between the latencies of R_1 component of BR that exceeded 1.2 ms was considered to be abnormal. The difference between values for R_2 latencies exceeding 5ms was accepted to be abnormal.⁸

To observe the presence of synkinetic spread, multichannel surface EMG (SEMG) recordings were made at rest and during the voluntary activities including eye closing and lip motion. Spasm activity was also recorded at the same position. At least three channels of muscle activity were recorded simultaneously. Input sensitivity was 100 or 200 μ V, sweep speed was between 20 ms -100 ms and upper and lower frequency bands were chosen as 5 kHz and 20 Hz. Discharge patterns of the spasm activities were grouped according to the electrophysiological appearance as isolated single, clustered rapid burst, and tonic spasms.

A statistical analysis of the distribution of discharge type according to gender and symptom duration was made to ascertain any differences. Statistical analysis was done using Graph Pad Prisma V.3. In addition to descriptive statistical methods (mean, standard deviation), the Kruskal Wallis test was also used for inter group comparisons; Dunn's multiple comparison test was used for comparison of subgroups, chi-square test was used for comparison of qualitative data and the Spearman correlation test was used to determine the correlation of the variables. A value of $p < 0,05$ was used for statistical significance. The confidence interval was found to be 95%.

RESULTS

The duration of symptoms before the examination was 1 month to 43 years, with a mean 4.3 years. Total of 87 male (age between 20 - 76, mean 49.7 ± 15.4 , disease duration $4,7 \pm 6,5$ years), and 119 female (age between 23 -75, mean 52.9 ± 11.1 , disease duration

Table 1: Early and late blink reflex latencies in subjects on spasm and unaffected sides.

	Female (ms)	Male (ms)	Total (ms)
R_1 Spasm side	10,7 \pm 1,6	11,2 \pm 1,3	10,9 \pm 1,5
R_1 Unaffected side	10,3 \pm 1,4	10,5 \pm 1,7	10,4 \pm 1,5
R_2 Spasm side	32,9 \pm 6,6	33,8 \pm 5,7	33,2 \pm 6,2
R_2 Unaffected side	32,7 \pm 5,7	32,3 \pm 4,7	32,4 \pm 5,1

3,9 \pm 4 years) patients were studied. None of the patients in our study group revealed a history of Bell's palsy. No significant differences were observed between female and male patients regarding the age at onset, duration of symptoms and the side predilection of the disease. In our series, three cases of bilateral HFS were found. Two of these cases were diagnosed clinically, and one subject diagnosed electrophysiologically. Two of these had tortuous blood vessels. In these patients, the spasms on the two sides were asynchronous and asymmetric, and spasm activity patterns were different.

In two of these patients, symptoms began at different times. No clinically evident associated movements were observed in 10 cases. Symptom duration was less than 1 year in 5 of these subjects.

Electrophysiological studies

Blink reflex: The mean values of early and late responses were within the normal range on both the spasm and unaffected sides; however, individual patients had side-to-side differences and prolongation of latencies. R_1 latency was longer than 13 ms in 6 cases; one had bilateral prolongation. Twenty-two patients had more than 1.2 ms difference on the spasm side when the latency of the early response was measured. R_2 latency was longer than 42 ms in 11 cases. In 30 patients, the late response latencies were longer than 5 ms on the spasm side compared to unaffected side.

R_1 and R_2 latencies did not differ between both in spasm and unaffected sides statistically (Table 1). On the spasm side, supraorbital nerve stimulation produced a synkinetic response on the orbicularis oris muscle except 8 cases.

Surface EMG Recording

a- Voluntary movements: Facial nerve innervated muscles contract simultaneously in spasm side during the voluntary movements in patients with HFS. Four patients who did not present clinical synkinetic spread in voluntary movements, did show co-activation of facial muscles in polymyographic recordings. \rightarrow

Table 2: The distribution of the spasm activity in patients with single type or all three types of activities

	Male (n, %)	Female (n, %)	Total (n, %)
Isolated discharge	16 (36.4)	21 (42.9)	37 (39.8)
Group discharge (burst)	14 (31.8)	20 (40.8)	34 (36.6)
Tonic spasm discharge	2 (4.5)	2 (4.1)	4 (4.3)
All 3 groups of discharge	12 (27.3)	6 (12.2)	18 (19.8)
Total	44	49	93

Table 3: The relationship between the spasm activity and mean disease duration

Discharge patterns	Symptom duration (Mean±SD)
Isolated discharge (n: 37)	1.56±1.79
Group discharge (burst)* (n: 34)	5.07±5.11
Tonic spasm discharge (n: 4)	10.38±6.05
All 3 groups of discharge (n: 18)	5.32±5.21

*High frequency bursts

b- Spasm activity: Except in 3 cases, spasm activity was recorded synchronously in both the orbicularis oculi and orbicularis oris muscles. In 2 of these 3 exception cases, spasms were observed only around the orbicularis oculi and around orbicularis oris in one. These subjects had symptom durations less than 6 months.

Isolated discharges were noted in 122 cases (Figure 1a,1b) and burst discharges in 148 cases (Figure 2a, 2b, 2c, 2d). Our observations showed that this type of activity was sometimes related to the eye blink and sometimes independent of it. Tonic spasms were recorded in 60 cases, 27 of which were in the motor unit frequency (Figure 3c). Spasm activity was not limited to one type in the large majority of the cases (131; 63.5%) (Figure 3a, 3b, 3c). Since many patients presented more than one type of activity, 75 cases that presented only one type of activity and 18 cases that presented all three were separated in order to determine the differences (Table 2).

The symptom durations of these cases were compared statistically. Isolated single discharges were found to be statistically significant in the earlier period of the disease (p=0.028). As the symptom duration increased, tonic spasms became more pronounced (p=0.032) and, in some cases, an interference pattern was observed (Table 3). The group that presented all three types of activities showed similar average symptom duration to that of the individuals with burst discharges. As seen in Table 3, each group shows major standard deviations for their mean symptom duration.

DISCUSSION

Definitive characteristics of HFS are the presence of spasms and the spread of voluntary and induced motor activity.¹ We concur with this view; however, we have noted that in cases where spasms in the very early stages occurred around the orbicularis oculi, synkinetic spread appeared after a while. In line with the literature, we have also observed that spasms start in the lower part of the orbicularis oculi, with fewer cases showing start around the edge of the orbicularis oris.^{9,10}

A variety of conclusions are found in the literature on the early and late response latencies of BR in HFS. Some authors have reported increased latency of R₁ on the spasm side.¹¹ Others believe that the R₁ latency remains normal on the spasm side in most of patients with HFS.^{12,13} Shorter R₂ latencies on the spasm side have also been reported.¹² The mean values of early and late responses of BR were within the normal range on both the spasm and the unaffected sides in our series. Our observations showed variations in early and/or late latencies in some cases; however, individual differences may not be significant in wide series.

Simultaneous recording from the orbicularis oculi and orbicularis oris verified the lateral spread of BR.¹³ Synkinesia has been reported in 70% of cases with HFS.¹¹ Supraorbital nerve stimulation produced a synkinetic contraction of orbicularis oris on the spasm side except 8 cases in our series. The characteristic EMG activity of HFS is the synchronized activity of motor units of facial muscles with a very high firing rate. It is generally accepted that the discharges may consist of a few motor units or may be synchronized discharges causing long-duration spasms.³ Among our cases, the most frequently encountered activity was clustered bursts with high frequency. There is no significance between the symptom duration and predominance of clustered burst activity. We assume that the isolated single discharges might be pre-discharges of the high-frequency group activity before the clustering. On the other hand, the interference pattern might have different source than the characteristic rapid bursts. Isolated single motor unit discharges were especially predominant in recent onset cases. This predominance was found to be statistically significant in the earlier period of the disease, whereas in chronic cases, spasm activity with a long lasting interference pattern was more pronounced.

While the mechanism of HFS is still controversial, it is believed to be caused by vascular compression of the facial nerve at the root exit zone. There are two hypotheses for this mechanism: In the peripheral hypothesis, compression of the facial nerve causes →

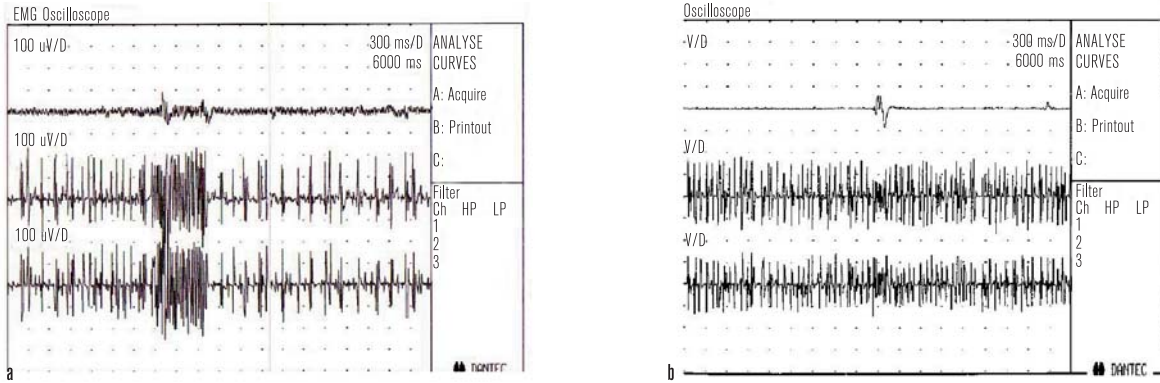


Figure 1. Isolated single bursts: 1a and 1b: recordings of two different patients with right sided HFS, Symptom durations were 2 years and 6 month, Channel 1: Right orbicularis oculi, Channel 2 Right orbicularis oris, Channel 3 Left orbicularis oculi (Contralateral side)

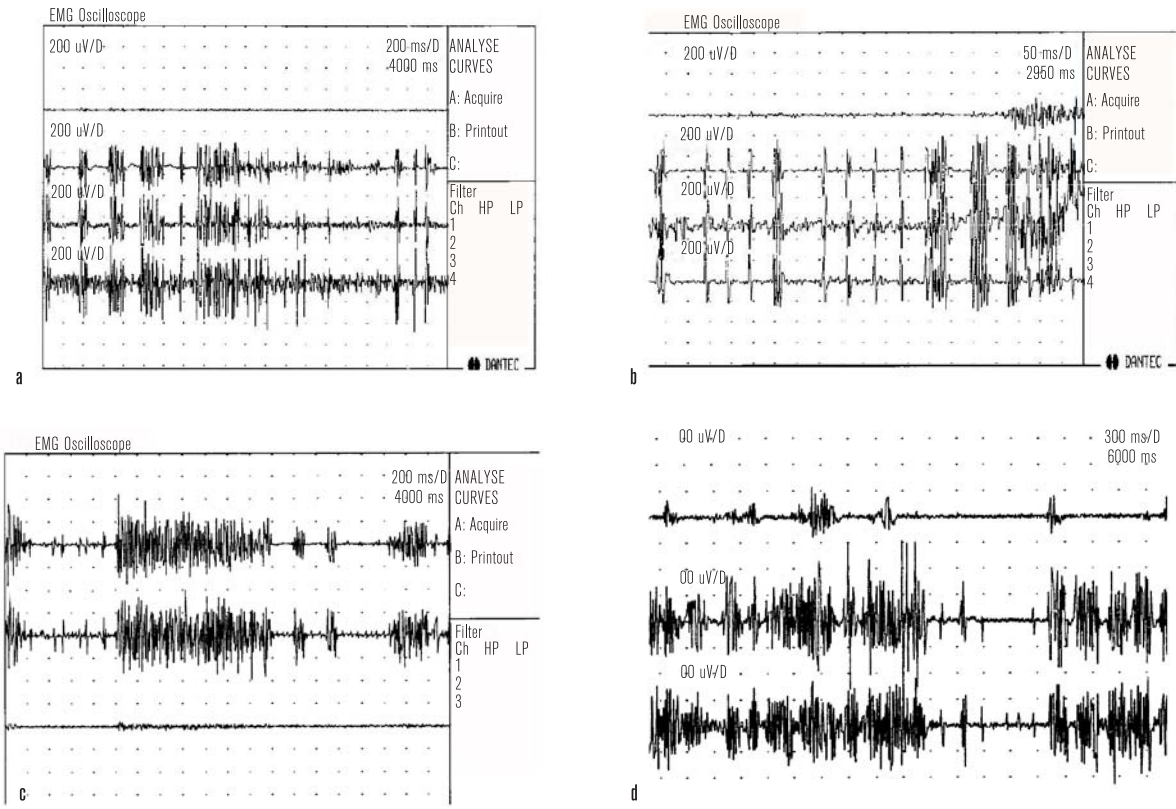


Figure 2. Group dyscharges (Clustered rapid bursts): 1a and b group dyscharges in patient right sided HFS, Symptom duration was 3 years. Channels: L Ooc, R ooc, R oor, R platysma. 1:c 55 Years old female, left sided HFS., Isolated, and prolonged group dyscharges 2,d. Blink bursts and group dyscharges in patients with R sided HFS with the symptom duration 5 years, Channels: Left orbicularis oculi (Contralateral side), Left orbicularis oris and Right orbicularis oculi

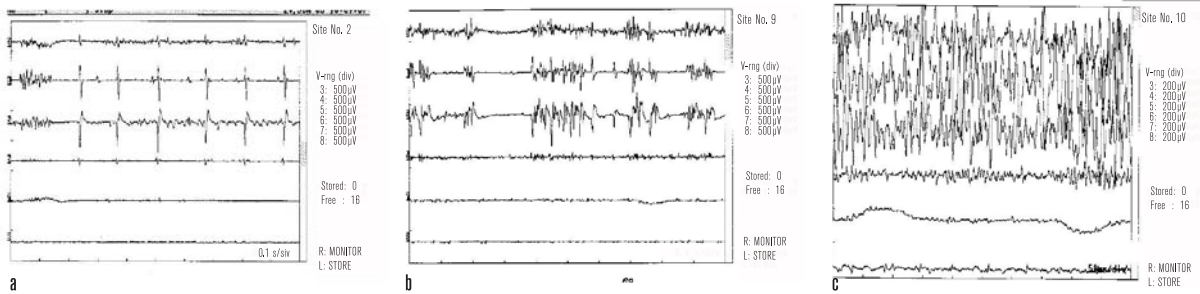


Figure 3. a,b,c : Isolated, group and tonic spasm (interference pattern) in the same patients with left sided HFS, Channels: L ooc, oor, posterior auricular muscle, R ooc, oor, posterior auricular muscle (Contralateral side).

hyperexcitability of the facial nucleus and spasm.^{14,15} Ephaptic transmission between individual nerve fibres and ectopic excitation induced by the compression causes abnormal spasm.^{11,16-18} The central or nucleus theory states that the peripheral injury of the facial nerve induces a functional reorganization of synapses within the facial nucleus, which is associated with a general hyperexcitability of the whole motor neuron pool. Hyperexcitability of the facial neuron and interneurons have been demonstrated.^{12,13}

Burst of action potentials with a high frequency have been reported to occur in afferent fibres in spinal roots of mutant mice.^{19,20} In HFS, local demyelination induced by the nerve injury permits ectopic insertion of Na⁺ channels, causes hyperexcitable nerve fibres at this level.²¹ On the other hand ectopic and abnormal peripheral neural activity induces increased excitability in the facial motor nucleus by creating a sustained antidromic activation of the neurons.²² High frequency discharges recorded from the muscles innervated by facial nerve may originate from the facial nerve axons, whereas interference pattern is related to the activity of the facial motor neurons or their supranuclear control.

This activity is more frequently seen in cases with longer symptom durations, which may be related with the facial motor neurons becoming hyperexcitable with antidromic impulses and becoming activated spontaneously. Based upon our present observations, it is not possible to reject any of these hypotheses for HFS.

Marti et al. reported the clinical severity scale of HFS in 1988.²³ It is possible to generate a rating scale based upon the electrophysiological characteristics. However, it is better to observe the development of the clinical and electrophysiological picture of the individual cases serially for this approach.

Polymyographic EMG recording is used to record voluntary or involuntary movements as desired. This testing is not invasive if surface electrodes are used, as preferred generally, and may be utilized in any EMG laboratory. Reflex activity such as BR may be examined with the same electrode position. HFS is a condition essentially diagnosed by clinical findings; however, investigations of the reflexes and the presentation of the types of spasm activity and its spread allow for better diagnosis of the patient.



C	CORRESPONDING AUTHOR: Nurten Uzun Assoc. Prof. MD Mesa Kemberburgaz Evleri Lavanta 2/1 34074 Gokturk Eyup Istanbul /TURKEY tadatepe@tinet.net.tr
✓	DELIVERING DATE: 07 / 06 / 2009 • ACCEPTED DATE: 15 / 09 / 2009

REFERENCES

- Auger RG. Hemifacial spasm: clinical and electrophysiological observations. *Neurology* 1979; 29: 1261-1272.
- Kimura J. Blink reflex in facial dyskinesia. *Adv. in Neurol.* Vol 49. In: Jankovic J, Tolosa E, eds. *Facial dyskinesias*. New York: Raven Press, 1988: 39-63.
- Aramideh M, Valls-Sole J, Cruccu G, Ongerboer de Visser BW. Assessment of the cranial nerves. In: Brown WF, Bolton CF, Aminof MJ, eds. *Neuromuscular function and disease*. Philadelphia: W.B Saunders Comp, 2002: 757-780.
- Hjorth RJ, Willison RG. The electromyogram in facial myokymia and hemifacial spasm. *J Neurol Sci* 1973; 20: 117-126.
- Blumental F, Mark May. Electrodiagnosis. In: May M, ed *The Facial nerve*. New York: Thieme, 1986: 241-263.
- Roth G, Magistris MR, Pinelli P, Rilliet B. Cryptogenic hemifacial spasm. A neurophysiological study. *Electromyogr Clin Neurophysiol* 1990; 30: 361-370.
- Sivak M, Ochoa J, Fernandez JM. Positive manifestations of nerve fiber dysfunction: Clinical electrophysiologic and pathologic correlates. In: Brown WF, Bolton CF, eds. *Clinical electromyography*. Boston: Butterworth-Heinemann, 1993: 117-147.
- Preston DC, Shapiro BE. Blink reflex. In: Preston DC, Shapiro BE. *Electromyography and neuromuscular disorders*. Clinical-electrophysiological correlations. Philadelphia, Pennsylvania: Elsevier, 2005: 59-64.
- Schulze- Bonhage A, Ferbert A. Electrophysiological recordings in bilateral hemifacial spasm. *J Neurol Neurosurg Psychiatry* 1998; 65: 408-410.
- Tan EK, Jankovic J. Bilateral hemifacial spasm: A report of five cases and a literature review. *Mov Disord* 1999; 14: 345-349.
- Nielsen VK. Pathophysiology of hemifacial spasm: II. Lateral spread of the supraorbital nerve reflex. *Neurology* 1984; 34: 427-431.
- Valls-Sole J, Tolosa ES. Blink reflex excitability cycle in hemifacial spasm. *Neurology* 1989; 39: 1061-1066.
- Ishikawa M, Ohira T, Namiki J, et al. Electrophysiological investigation of hemifacial spasm: F-waves of facial muscles. *Acta Neurochir* 1996; 138: 24-32.
- Ferguson J.H. Hemifacial spasm and the facial nucleus. *Ann Neurol* 1978; 4: 97-103.
- Ishikawa M, Ohira T, Namiki J, et al. F- wave in patients with hemifacial spasm: Observations during microvascular decompression operations. *Neurol Res* 1996; 18: 2-8.
- Nielsen VK. Pathophysiology of hemifacial spasm: I. Ephaptic transmission and ectopic excitation. *Neurology* 1984; 34: 418-426.
- Nielsen VK, Janetta PJ. Pathophysiology of hemifacial spasm: III. Effects of facial nerve decompression. *Neurology* 1984; 34: 891-897.
- Nielsen VK. Electrophysiology of the facial nerve in hemifacial spasm: Ectopic/ephaptic excitation. *Muscle Nerve* 1985; 8: 545-555.
- Rasninsky M. Ectopic generation of impulses and cross-talk in spinal nerve roots of "dystrophic" mice. *Ann Neurol* 1978; 3: 351-357.
- Rasninsky M. Ephaptic transmission between single nerve fibres in the spinal nerve roots of dystrophic mice. *J Physiol* 1980; 305: 151-169.
- Rasninsky M. Physiological properties of dystrophic mouse spinal root axons. *Electroencephalogr Clin Neurophysiol Suppl* 1982; 36: 99-105.
- Geller B.D, Hallet M, Ravits J. Botulinum toxin therapy in hemifacial spasm: Clinical and electrophysiologic studies. *Muscle Nerve* 1989; 12: 716-22.
- Marti MJ, Tolosa E, Alom J. Botulinum toxin in hemifacial spasm: A Double blind controlled trial. In. Barhtko D, Turcany T, Stern G, eds. *New trends in neuropharmacology*. London: John Libbey Co, 1988: 304-307.