

# ACHALASIA AND THYROID DISEASE: COMMON ETIOLOGY OR ONLY COINCIDENCE?

Gülbanu Erkan MD,<sup>1</sup> İbrahim Doğan Assoc. Prof. MD,<sup>1</sup> Salih İnal MD,<sup>1</sup> Mustafa Cesur Assoc. Prof. MD,<sup>2</sup> Mehmet Cindoruk Assoc. Prof. MD,<sup>1</sup> Aylar Poyraz Assoc. Prof. MD,<sup>3</sup> Selahattin Ünal Prof. MD<sup>1</sup>

<sup>1</sup> Gazi University Hospital, Faculty of Medicine, Department of Gastroenterology, Ankara, Turkey

<sup>2</sup> Ankara Guven Hospital, Department of Endocrinology, Ankara, Turkey

<sup>3</sup> Gazi University Hospital, Faculty of Medicine, Department of Pathology, Ankara, Turkey

## ABSTRACT

A 47-year-old woman sought medical attention because of progressive dysphagia for solids and liquids. She had lost 7 kilograms within the last three months. The physical examination was normal, except an enlarged and nodular thyroid gland. The patient's endoscopic, manometric, and barium swallow studies results were consistent with achalasia. She underwent fine needle aspiration biopsy (FNAB) due to a nodule in the right lobe of the thyroid

gland and the cytological examination was reported as lymphocytic thyroiditis. There are few reports about achalasia and accompanying autoimmune thyroid diseases.

Because autoimmunity is important in the etiopathogenesis of this disease, the clinician should be on alert for autoimmune thyroid disorders in a patient with achalasia.

**Key Words:** Esophageal achalasia, thyroid diseases, autoimmunity. *Nobel Med* 2011; 7(3): 108-110

## AKALAZYA VE TİROİD HASTALIĞI: ORTAK ETYOLOJİ YA DA RASTLANTISAL BİRLİKTELİK?

### ÖZET

Kırkyedi yaşında kadın hasta katı ve sıvı gıdalara karşı yutma güçlüğü yakınmasıyla başvurdu. Son 3 ay içinde 7 kilogram zayıflamıştı. Fizik muayenesi büyümüş ve nodüler tiroid glandı dışında normaldi. Endoskopik, manometrik incelemeler ve baryum'lu özofagus grafisi sonuçları akalazyaya ile uyumluydu. Tiroid glandının sağ lobundaki nodüle ince iğne aspirasyon biyopsisi yapıldı ve sitolojik incelemede lenfositik tiroidit olarak saptandı. Akalazyaya eşlik eden otoimmün tiroid hastalıklarıyla ilgili az sayıda yayın bulunmaktadır.

Etiyopatogenezinde otoimmünite de rol aldığı için akalazyalı bir hastada otoimmün tiroid hastalıkları da araştırmak gereklidir.

**Anahtar Kelimeler:** Özofageal akalazyaya, tiroid hastalıkları, otoimmünite *Nobel Med* 2011; 7(3): 108-110

## INTRODUCTION

Achalasia is a common and well characterized primary motility disorder of esophageal body and lower esophageal sphincter (LES) involving absence of progressive peristalsis in the esophageal body and abnormal relaxations of the LES.<sup>1,2</sup> While achalasia is a long recognized clinical entity, the underlying pathophysiology remains poorly understood.<sup>3</sup> Proposed causes of achalasia include neuronal degeneration, viral infection, genetic inheritance, and autoimmune disease. Thus, achalasia may be linked to other autoimmune conditions. There are few reports on the association of achalasia with autoimmune thyroiditis. We present a case of achalasia accompanied

by focal lymphocytic thyroiditis, a variation of autoimmune thyroiditis.

## CASE REPORT

A 47-year-old woman was admitted to the hospital with progressive dysphagia for solid and liquid food and unintended weight loss of approximately 7 kg during the last 3 months. The medical history was unremarkable for any systemic disorders or medications. The physical examination on admission revealed a bilaterally, diffusely enlarged thyroid gland and a nodule approximately 1 cm in diameter in the right lobe, but otherwise was unremarkable. Laboratory data including complete blood count, biochemical assays and thyroid→

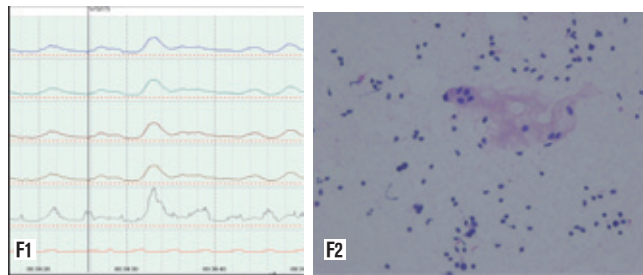
function tests were in normal ranges. Thyroid peroxidase antibody (anti-TPO) level was 34.43 IU/ml (0-115) and antithyroglobulin (anti-TG) antibody level was 21.38 IU/ml (0-34). Due to the complaint of dysphagia, upper gastrointestinal endoscopy, pharyngoesophagogram and esophageal manometry were performed. Plain abdominal X ray showed absence of gas in the stomach. Endoscopy indicated normal esophageal and cardiac mucosa with no evidence of esophagitis, but revealed antral gastritis. Esophagogram (barium swallowed) showed a markedly dilated esophageal body with a beak-like narrowing of the terminal portion, both typical findings of achalasia. Esophageal manometry showed that lower esophageal sphincter (LES) pressure was high and that LES relaxation was impaired during swallowing. Mean LES pressure was calculated as 60 mmHg and the amplitude of contractions on esophageal body was low and all of the contractions were simultaneous, suggestive of achalasia (Figure 1). With the clinical, radiological and manometric findings all suggestive of achalasia, diagnosis of esophageal achalasia (EA) was established.

Ultrasonography demonstrated that the thyroid gland was enlarged (right lobe=19x22x51 mm, left lobe=15x18x62 mm) with a heterogeneous iso-echoic solid nodule in right lobe (13x10 mm). She underwent fine needle aspiration biopsy (FNAB) and the cytological examination revealed lymphocytic thyroiditis (Figure 2).

For the treatment of the achalasia, pneumatic dilatation was performed using 30 mm Rigiflex balloon dilator (one minute, two times). In the follow up, her symptoms were controlled and weight gain was achieved.

## DISCUSSION

Achalasia is a common and well characterized primary motility disorder of esophageal body and lower esophageal sphincter (LES) involving absence of progressive peristalsis in the esophageal body and abnormal relaxations of the LES.<sup>1,2</sup> While achalasia is a long recognized clinical entity the underlying pathophysiology remains poorly understood.<sup>3</sup> Proposed causes of achalasia include neuronal degeneration, viral infection, genetic inheritance, and autoimmune disease. The association of achalasia and thyroid disease has been known for a long time.<sup>4</sup> Hypothyroidism may also lead to megaesophagus caused by generalized neuropathy and that responds well to thyroxin treatment.<sup>5</sup> Current evidence suggests that the initial insult to the esophagus, perhaps a viral infection or some environmental factor, results in myenteric plexus inflammation. The inflammation



**Figure 1.** Manometric findings of the patient **Figure 2.** Histopathologic examination of the thyroid gland displaying Hurthle cells and lymphocytes (HEx100)

then leads to an autoimmune response in a susceptible population who may be genetically predisposed. Subsequently, chronic inflammation leads to destruction of the inhibitory myenteric ganglion cells resulting in the clinical syndrome of achalasia.<sup>6</sup> Evidence of autoimmune etiology of achalasia is based on the presence of circulating autoantibodies against the myenteric plexus, presence of inflammatory T-cell infiltrates in the myenteric plexus and increased prevalence of HLA class II antigens.<sup>6</sup>

Hashimoto's thyroiditis is the most common form of autoimmune thyroiditis characterized by diffuse lymphocytic infiltration, lymphoid follicle formation, epithelial cell destruction, fibrous tissue proliferation and presence of thyroid autoantibodies.<sup>7</sup> HLA-DR polymorphisms are the best documented genetic risk factors for autoimmune hypothyroidism. A weak association also exists between polymorphism in CTLA-4, a T cell regulating gene and autoimmune hypothyroidism. Both of these genetic associations are shared by other autoimmune diseases, which may explain the relationship between autoimmune hypothyroidism and other autoimmune diseases especially type 1 diabetes mellitus, Addison disease, pernicious anemia and vitiligo.<sup>8</sup>

Histopathologically proven autoantibody negative Hashimoto's thyroiditis has been reported.<sup>9,10</sup> It has been proposed that local antibody production by lymphocytes in the thyroid gland causes the thyroiditis without evidence of systemic immune response.<sup>9,10</sup> Thus, Hashimoto's thyroiditis can exist as an organ restricted autoimmune disorder.<sup>9</sup> In a group of 109 patients with Hashimoto's thyroiditis the anti-TG antibodies were not detected in 14.67% and anti-TPO in 21.1% of patients. Both antibodies were negative in 1.83% of the patients.<sup>11</sup>

There are a few reports about achalasia and other concomitant autoimmune diseases, which are Sjogren's syndrome, scleroderma, myasthenia gravis, polymyositis, and Allgrove Syndrome.<sup>12-14</sup> Allgrove syndrome is a rare hereditary syndrome described →

**ACHALASIA AND  
THYROID DISEASE:  
COMMON ETIOLOGY OR  
ONLY COINCIDENCE?**

the presence of sicca syndrome, neuropathy, esophageal achalasia and ACTH insensitivity.<sup>15,16</sup>

Emami et al. reported the association of achalasia and different forms of thyroid disease.<sup>17</sup> Seven out of 30 patients (23%) had thyroid disease including four patients with hypothyroidism (13.3%), two patients with hyperthyroidism (6.6%), and one had only thyroid nodule but was in euthyroid state (3.3%). The form or severity of the thyroid disease was not related to the severity of achalasia symptoms. However, the autoantibody states of the patients is not available in this report. Moreover, there have been three different studies in which autoimmune thyroid disease was studied in achalasia and the incidence rate was found to be approximately 10%.<sup>18-20</sup>

Our case was a cytologically proven lymphocytic thyroiditis as it displayed extensive lymphocytes with accompanying Hurthle cells which is specific to autoimmune thyroiditis.<sup>21</sup> For the limited infiltration confined to the thyroid nodule, we diagnosed focal lymphocytic thyroiditis. In autoimmune thyroiditis, infiltrating lymphocytes have an important role in the formation of the disease since they are

known to release cytokines which can alter thyroid functions. The degree and site of lymphocytic infiltration in the thyroid gland have been used to differentiate between Hashimoto's disease and focal lymphocytic thyroiditis. Actually, focal lymphocytic thyroiditis is represented as part of the spectrum of autoimmune thyroiditis and Hashimoto's thyroiditis.<sup>22</sup> The ultrasound image of the thyroid gland in our case also supports the diagnosis of focal thyroiditis with its normal thyroid echogenicity and heterogeneous focal area. The cardinal finding of ultrasound image in histologically proven focal thyroiditis is the normal echogenicity of the thyroid gland with a micronodular pattern as shown in previous studies.<sup>23,24</sup>

## CONCLUSION

There are few reports on the association of achalasia and autoimmune thyroiditis. We present a case of achalasia and cytologically proven focal lymphocytic thyroiditis. While we acknowledge that this may be a coincidence, autoimmunity can be a common etiology and a link between these two disorders. We suggest that autoimmune thyroid disease should be investigated in patients with achalasia.

<b>C</b>	<b>CORRESPONDING AUTHOR:</b> Gülbano Erkan MD 60. Sokak 22/3 06510 Emek, Ankara, Turkey gcanbaloglu@yahoo.com
<b>✓</b>	<b>DELIVERING DATE:</b> 15 / 07 / 2009 • <b>ACCEPTED DATE:</b> 05 / 01 / 2010

## REFERENCES

- Moses PL, Ellis LM, Anees MR, et al. Antineuronal antibodies in idiopathic achalasia and gastro-oesophageal reflux disease. *Gut* 2003; 52: 629-636.
- Baykal Y, Ozet G, Ozdemir C. The enteric nervous system and its role in related diseases. *Turkiye Klinikleri J Med Sci* 1999; 19: 40-47.
- Podas T, Eaden J, Mayberry M. Achalasia: a critical review of epidemiological studies. *Am J Gastroenterol* 1998; 93: 2345-2347.
- Schomerus H, Kallee E, Wahl E, Doelle W. Achalasia and the thyroid gland. *Verh Dtsch Ges Inn Med* 1978; 84: 1601-1603.
- Jaggy A, Oliver JE. Neurologic manifestations of thyroid disease. *Vet Clin North Am Small Anim Pract* 1994; 24: 487-494.
- Park W, Vaezi MF. Etiology and Pathogenesis of Achalasia: The current understanding. *Am J Gastroenterol* 2005; 100: 1404-1414.
- Pearce EN, Farwell MD, Braverman LE. Thyroiditis. *N Eng J Med* 2003; 348: 2646-2655.
- Jameson JL, Weetman AP. Disorders of the thyroid gland. *Harrison's Principles of Internal Medicine*. Kasper DL, Braunwald E, Fauci AS 16th Edition. Mc Graw-Hill Company, Inc. 2005; 2110-2111.
- Baker JR Jr, Saunders NB, Wartofsky L, Tseng YC, Burman KD. Seronegative Hashimoto thyroiditis with thyroid autoantibody production localized to the thyroid. *Ann Intern Med* 1988; 108: 26-30.
- Spina MP, Cerri A, Piacentini V, Stringa A, Visca U. Seronegative hashitoxicosis in patient with rheumatoid arthritis. *Minerva Endocrinol* 1990; 15: 173-176.
- Lastrzewska-Bohaterewicz E, Wojciechowska W, Gardas A. Place of thyroglobulin antibodies assay in laboratory diagnostic of autoimmune thyroid diseases. *Endokrynol Pol* 2005; 56: 30-34.
- Poglio F, Mongini T, Cocito D. Sensory ataxic neuropathy and esophageal achalasia in a patient with Sjogren's syndrome. *Muscle Nerve* 2007; 35: 532-535.
- Gockel I, Bork K, Eckardt VF, Junginger T. Achalasia in circumscribed scleroderma. *Dtsch Med Wochenschr* 2006; 131: 1799-1802.
- Kornizky Y, Heller I, Isakov A, Shapira I, Topilsky M. Dysphagia with multiple autoimmune disease. *Clin Rheumatol* 2000; 19: 321-323.
- Allgrove J, Clayden GS, Grant DB, Macaulay JC. Familial glucocorticoid deficiency with achalasia of the cardia and deficient tear production. *Lancet* 1978; 1: 1284-1286.
- Kimber J, McLean BN, Prevett M, Hammans SR. Allgrove or 4 "A" syndrome: an autosomal recessive syndrome causing multisystem neurological disease. *J Neurol Neurosurg Psychiatry* 2003; 74: 654-665.
- Emami MH, Raisi M, Amini J, Daghighzadeh H. Achalasia and thyroid disease. *World J Gastroenterol* 2007; 13: 594-599.
- Kroupa R, Stary K, Hep A, Suchánková J, Dolina J. Higher incidence of thyropathy in patients with oesophageal achalasia. Genetic, autoimmune, regional or just a random association? *Vnitr Lek* 2008; 54: 341-345.
- Dhamija R, Tan KM, Pittcock SJ, et al. Serologic profiles aiding the diagnosis of autoimmune gastrointestinal dysmotility. *Clin Gastroenterol Hepatol* 2008; 6: 988-992.
- Ho KY, Tay HH, Kang JY. A prospective study of the clinical features, manometric findings, incidence and prevalence of achalasia in Singapore. *J Gastroenterol Hepatol* 1999; 14: 791-795.
- Baloch ZW, LiVolsi VA, Asa SL, et al. Diagnostic terminology and morphologic criteria for cytologic diagnosis of thyroid lesions: a synopsis of the National Cancer Institute Thyroid Fine-Needle Aspiration State of the Science Conference. *Diagn Cytopathol* 2008; 36: 425-437.
- Bay BH, Sit KH, Pang AS. Lymphocytic infiltration in focal thyroiditis: an ultrastructural case study. *Immunobiology* 1994; 190: 290-294.
- Marcocci C, Vitti P, Cetani F, et al. Thyroid ultrasonography helps to identify patients with diffuse lymphocytic thyroiditis who are prone to develop hypothyroidism. *J Clin Endocrinol Metab* 1991; 72: 209-213.
- Langer JE, Khan A, Nisenbaum HL, et al. Sonographic appearance of focal thyroiditis. *AJR Am J Roentgenol* 2001; 176: 751-754.