

NOT ALL SPELLS ARE EPILEPTIC IN DEVASTATING NEUROLOGICAL DISORDERS: BREATH-HOLDING SPELLS IN INFANTILE NEUROAXONAL DYSTROPHY

Veysi Demirbilek, Gülçin Benbir, Aysin Dervent

Istanbul University, Cerrahpaşa Faculty of Medicine, Department of Neurology, Istanbul, Turkey

ABSTRACT

Breath-holding spells are episodes of brief, involuntary cessations of breathing that occur in children in response to stimuli such as fear or injury. They are usually benign, and although very rarely, breath-holding spells accompany deteriorative neurological diseases.

Here, we present two patients having infantile neuroaxonal dystrophy and breath-holding spells. Presence of the common respiratory problems in children with neurological disabilities may predispose the child with breath-holding spells and infantile neuroaxonal dystrophy to a danger of

prolonged apnea and may be to a life-threatening event. Careful discrimination of breath-holding spells from true epileptic seizures need special emphasis, since acute delivery of antiepileptic drugs such as phenobarbitone or benzodiazepines may have further disturbing effects on respiration. It should be kept in mind that not every tonic or clonic movements are epileptic, and benign non-epileptic fits such as breath-holding spells may also co-exist in progressively deteriorating childhood disorders including infantile neuroaxonal dystrophy.

Key Words: Breath-holding spells, infantile neuroaxonal dystrophy, epilepsy. *Nobel Med 2014; 10(1): 79-81*

İNFANTİL NÖROAKSONAL DİSTROFİDE SOLUK TUTMA ATAKLARI: KÖTÜ SEYİRLİ NÖROLOJİK HASTALARDA GÖRÜLEN HER NÖBET EPİLEPTİK DEĞİLDİR

ÖZET

Soluk tutma atakları, çocuklarda korku veya zarar görme gibi bir uyarana yanıt olarak nefes almanın istemsiz olarak kısa süreli durması ile şekillenen ataklardır. Genellikle iyi huyludur, ancak nadiren de olsa ilerleyici nörolojik hastalıklarda da görülebilir.

Burada, infantil nöroaksonal distrofi tanısı almış ve soluk tutma atakları olan iki hastayı sunmaktayız. Nörolojik bozuklukları olan çocuklarda sıklıkla görülen

solunum problemleri, soluk tutma ataklarına yatkınlık oluşturabilmektedir ve infantil nöroaksonal distrofide uzun süren bir apne hayati önem taşımaktadır.

Soluk tutma ataklarının epileptik nöbetlerden dikkatli bir şekilde ayırt edilmesi gereklidir; nitekim fenobarbital veya benzodiyazepin gibi antiepileptik ilaçların başlanması, solunum üzerinde ek negatif bir etki oluşturacaktır. Her tonik veya klonik kasılmanın epileptik bir nöbet olmayabileceği ve soluk tutma atakları gibi iyi huylu epileptik olmayan atakların da, infantil nöroaksonal distrofi gibi ilerleyici nörolojik hastalıklara eşlik edebileceği akılda tutulmalıdır.

Anahtar Kelimeler: Soluk tutma atakları, infantil nöroaksonal distrofi, epilepsi. *Nobel Med 2014; 10(1): 79-81*

INTRODUCTION

Breath-holding spells (BHS) are episodes of brief, involuntary cessations of breathing that occur in children in response to emotional stimuli, and are usually benign.^{1,2} The stereotypical clinical events begin with a provocation resulting in crying or an emotional upset leading to a noiseless state of expiration

accompanied by color change and ultimately loss of consciousness and postural tone.² BHS are considered to present two distinctive forms as cyanotic and pallid. In the more common cyanotic BHS, the child cries and she/he has forced expiration leading to cyanosis, limpness, and loss of consciousness caused by cerebral anoxia.^{1,3} This may be followed by a few seconds of rhythmic clonic jerking of the extremities,→

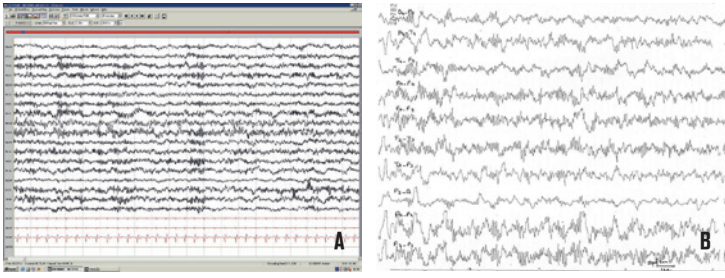


Figure 1A, 1B: Video-EEG of patient 1 showing diffuse fast rhythm within 16-18 Hz (A); Sleep EEG of patient 2 showing generalized fast rhythms characteristics for infantile neuroaxonal dystrophy (B).

mimicking seizure-like activity, or rigid opisthotonic posturing of the body. Although very rarely, BHS may accompany some deteriorative neurological diseases, such as infantile neuroaxonal dystrophy (INAD) or Rett syndrome.^{4,5} INAD (also known as Seitelberger Disease) is a rare inherited progressive degenerative disorder of childhood, characterized by the loss of previously acquired skills, psychomotor regression, progressive neuromuscular impairment, hypotonia, hyperreflexia, spasticity, and progressive paraplegia.⁶ In INAD epileptic seizures are rare and usually late and intricate events. They may be limited to episodic autonomic symptoms such as hypertension and flushing of the face.⁷ Neurophysiological findings include nonreactive fast rhythms (16-22 Hz) in the electroencephalogram during wakefulness and sleep. Although this rhythm is highly suggestive of INAD, it is not specific for the disease.⁶ Here, we present two patients having INAD and BHS, and discuss the comorbidity of those two conditions.

CASE REPORTS

Case 1

A 16-month-old boy was brought to our neurology department due to so-called seizures and regression in development. He was the 2nd child to a non-consanguineous marriage. He was born at term following an uncomplicated pregnancy and delivery. His past medical history was unremarkable. The family history revealed a maternal uncle with epilepsy and mental retardation.

His development was normal until about 12 months of age, when the parents noticed that he could no longer sit without support. The eye contact and the vocabulary memory of the patient were gradually decreased. The attacks were reported as seizures by the parents started two months before his admission, as tonic contractions in both arms and perioral cyanosis with subsequent fainting lasted shorter than one minute. Detailed questioning revealed that those attacks occurred only at the onset of crying episodes

and were interpreted as cyanotic breath holding spells. His neurological examination showed generalized hypotonia, normoactive deep-tendon reflexes and bilateral multidirectional nystagmus.

Video-EEG showed a diffuse fast rhythm within 16-18 Hz, nonreactive to eye opening and to photic stimuli during wakefulness and sleep (Figure 1A). Cranial magnetic resonance imaging (MRI) showed diffuse cortical hyperintensity with bilateral white matter hypomyelination and cerebellar atrophy, suggestive of neuroaxonal dystrophy. EMG revealed diffuse denervation with normal motor and sensory nerve conduction measures, suggestive of diffuse anterior horn cell and/or multiple radicular involvements.

Case 2

A two-year-old boy was brought with the complaints of developmental delay and so-called seizures. He was the only child of a non-consanguineous couple, born at term following an uncomplicated pregnancy and delivery. He had no remarkable past medical and family history. Since early neonatal period, he experienced generalized tonic contraction and cyanosis during crying. He was therefore treated by phenobarbital with a decrease in attack frequency, yet no total abolishment was observed. Cranial computed tomography and EEG at five months of age yielded unremarkable findings. At the age of one, he could not walk independently, followed by the loss of unsupported sitting and head-control. At the examination, he had severe psychomotor retardation, left-sided abducens palsy, nystagmus at left gaze, and generalized hypotonia with decreased deep tendon reflexes.

Cranial MRI showed delayed myelination and pathological hyperintensity on T2-weighted images over the periventricular white matter at the level of atrium. His repeated EEGs during wakefulness and sleep showed generalized 17-18 Hz fast activity, being more prominent over the anterior and posterior regions of both hemispheres (Figure 1B). Although the fast EEG activity was nonreactive to eye opening, photic stimulation or sleep, diffuse bioelectrical slowing with 2-3 Hz delta activity was observed during BHS (Figure 2). EMG revealed diffuse denervation with normal motor and sensory nerve conduction measures, suggestive of diffuse anterior horn cell and/or multiple radicular involvements. Sural nerve biopsy demonstrated the neuroaxonal dystrophy.

DISCUSSION

Breath holding spells in infants with INAD seem to be a condition that deserves attention in the differential →

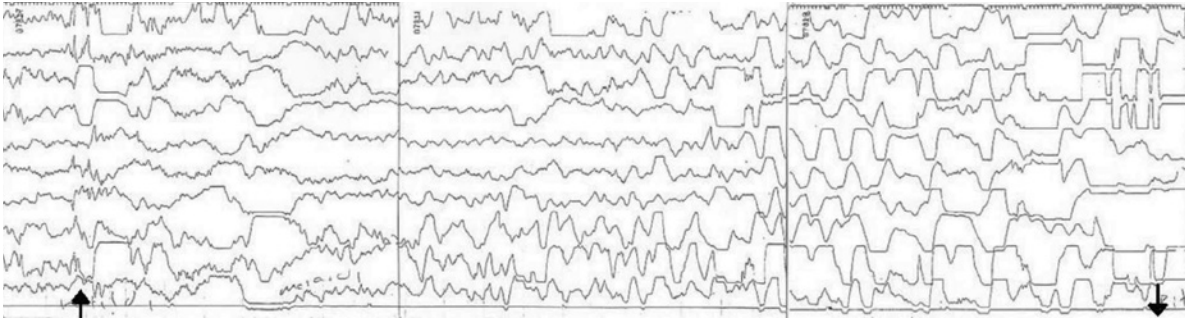


Figure 2: EEG of patient 2 during a breath holding spell, which shows the attenuation of the amplitudes and slowing of the EEG activity becoming more prominent towards to the end of the episode (↑: onset; ↓: end of the attack.).

diagnosis of non-epileptic paroxysmal events. On the other hand, true epileptic seizures may also be triggered following neurally-mediated syncope and the valsalva manoeuvre may also provoke a vibratory tonic epileptic seizure.⁸ Although isolated BHS are benign conditions, they may lead to serious consequences if they associate severe neurological conditions such as INAD and Rett syndrome.^{4,5} Among the respiratory problems commonly encountered in children with neurological impairments, recurrent aspiration due to oro-pharyngeal motor problems and/or gastro-oesophageal reflux, poor cough and airway clearance, respiratory muscle weakness, kyphoscoliosis and malnutrition leading to atrophy in the respiratory muscles, reduced lung function, increased bacterial colonization and the reduced resistance to infections are reported.⁹ Presence of one or more of such conditions may predispose the child with INAD and BHS to a danger of prolonged apnea during such a fit and may be life-threatening. Careful discrimination of BHS from true epileptic seizures therefore needs special emphasis, since the acute delivery of drugs such as phenobarbitone or benzodiazepines may have further disturbing effects on respiration.

In a paper by Ferriss and his colleagues, the authors noticed that the high-voltage fast EEG rhythm

unresponsive to eye opening or photic stimulation changed during crying and hypoxic spells and became slower; concluding that the characteristic EEG activity observed in INAD was responsive to chemical influences.⁴ Similarly, we observed that the EEG of patient 2 was not responsive to other stimuli, but showed generalized slowing during BHS. An underlying autonomic nervous system dysregulation was shown in children with cyanotic BHS, which may contribute for the pathophysiology of the occurrence of these spells in INAD.¹⁰

CONCLUSION

Breath holding spells are easily diagnosed in a child with normal motor and mental development; however, it should also be kept in mind for children with progressive devastating diseases, such as infantile neuroaxonal dystrophy. More than being comorbidity, progressive diffuse muscle hypotonia and the involvement of the autonomic nervous system in INAD may provide a predisposition for recurrent breath-holding attacks in these children.



C	CORRESPONDING AUTHOR: Gülçin Benbir Istanbul University Cerrahpaşa Faculty of Medicine, Department of Neurology, Istanbul, Turkey drgulcinbenbir@yahoo.com
✓	DELIVERING DATE: 05 / 08 / 2012 • ACCEPTED DATE: 24 / 06 / 2013

REFERENCES

- Di Mario FJ. Prospective study of children with cyanotic and pallid breath-holding spells. *Pediatrics* 2001; 107: 265-269.
- Lombroso CT, Lerman P. Breath-holding spells (cyanotic and pallid infantile syncope). *Pediatrics* 1967; 39: 563-581.
- Erdogan F, Yapici Z, Deniz E, et al. Infantile neuroaxonal dystrophy: report of two cases. *Eur J Paediatr Neurol* 1999; 3: A113.
- Ferriss GS, Happel LT, Duncan MC. Cerebral cortical isolation in infantile neuroaxonal dystrophy. *Electroencephalogr Clin Neurophysiol* 1977; 43: 168-182.
- Glaze DG, Schultz RJ, Frost JD. Rett syndrome: characterization of seizures versus non-seizures. *Electroencephalogr Clin Neurophysiol* 1998; 106: 79-83.
- Nardocci N, Zorzi G, Farina L, et al. Infantile neuroaxonal dystrophy. Clinical spectrum and diagnostic criteria. *Neurology* 1999; 52: 1472-1478.
- Santucci M, Ambrosetto G, Scaduto MC, et al. Ictal and non-ictal paroxysmal events in infantile neuroaxonal dystrophy: polygraphic study of a case. *Epilepsia* 2001; 42: 1074-1077.
- Stephenson J, Breningstall G, Steer C, et al. Anoxic-epileptic seizures: home video recordings of epileptic seizures induced by syncopes. *Epileptic Disord* 2004; 6: 15-19.
- Sullivan BP, Rosenbloom L. Feeding the disabled child. *Clinics in Developmental Medicine No 140*. Mac Keith Press, London. 1999.
- Di Mario FJ, Chee CM, Berman PH. Pallid breath-holding spells: Evaluation of the Autonomic Nervous System. *Clin Pediatr* 1990; 29: 17-24.