

# PREMENOPAUSAL FEMALE WITH BILATERAL MUCINOUS CANCER OF THE BREAST: THE FIRST CASE IN LITERATURE

Hakan Buluş,<sup>1</sup> Onur Birsen,<sup>2</sup> Ayşe Derya Buluş<sup>3</sup>

<sup>1</sup> Ankara Keçiören Research and Training Hospital, Department of General Surgery, Ankara

<sup>2</sup> Pamukkale University School of Medicine, Department of General Surgery, Denizli

<sup>3</sup> Ankara Keçiören Research and Training Hospital, Department of Pediatric Endocrinology, Ankara

## ABSTRACT

Few reports exist in the clinical literature characterizing a synchronous bilateral mucinous carcinoma of the breast however this is the first case of premenopausal woman with bilateral mucinous breast cancer in the literature. We

report a case of bilateral mucinous carcinoma of the breast which is seen very rarely.

**Key Words:** Bilateral breast neoplasms, synchronous breast cancer, mucinous carcinoma. *Nobel Med* 2014; 10(1): 97-98

## PREMENEPOZAL KADIN HASTADA MEMENİN BİLATERAL MÜSİNÖZ KANSERİ: LİTERATÜRDEKİ İLK OLGU

### ÖZET

Tip literatürde bir kaç adet senkron bilateral müsünöz meme kanseri ile karakterize olgu bildirilmiş fakat

premenopozal kadın hastada bilateral müsünöz meme kanseri ilk defa bildirilmiştir. Biz çok nadir görülen bilateral müsünöz meme karsinomlu kadın bir olguyu sunduk.

**Anahtar Kelimeler:** İki taraflı meme kanseri, senkron meme kanseri, müsünöz meme kanseri. *Nobel Med* 2014; 10(1): 97-98

## INTRODUCTION

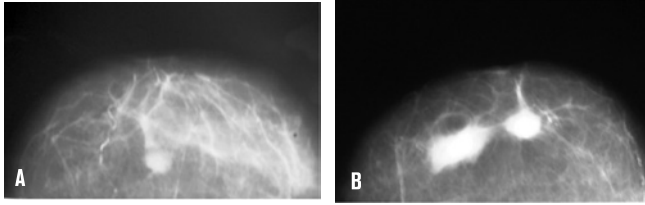
Mucinous cancer of the breast accounts for about 1-6% of all breast cancers and is a rare pathological sub-type.<sup>1</sup> This type of breast cancers is usually seen in women aged 75 and over.<sup>2</sup> Depending on the extracellular musin production, mucinous breast cancers are divided into two histological types as pure and mixed mucinous cancers. Studies have reported that pure type of mucinous breast cancers have a better prognosis than mixed type.<sup>3,4</sup> Although synchronous bilateral breast cancer in the literature is a rare clinical situation seen as approximately 1%, synchronous bilateral mucinous breast cancer in literature was reported only in one case.<sup>5,6</sup> We are presenting the 49-year-old female patient with bilateral mucinous breast cancer, which is a case seen very rarely.

## CASE REPORT

Our patient was a 49-year-old female with the complaints of swelling and pain in both breasts for 3 months. There was no family history. On physical examination, approximately 1.5 cm in size in the right breast on the localisation that fits the area over 3 o'clock, approximately 2 cm in size in

the left breast on the localisation of upper outer quadrant and approximately 3.5 cm in size in the left breast on the localisation of upper inner quadrant were detected as palpable masses. In the ultrasound imaging of the patient, 1 lesion as 15x14x12 mm in right breast and 2 homogenous hypochoic lesions as 35x28x19 mm and 19x16x14 mm in left breast were seen. There were radiopaque masses without spicule formation and microcalcifications in mammographic views of both breasts (BIRADS3) (Figure A-B). Fine needle aspiration biopsy was performed for the existing lesions in both breasts. As a result, mucinous carcinoma of the breast was reported for all lesions of both breasts. While the amount of CEA 15-3 of the patient was found as 44.15 U/ml (normal: 0-25 U/ml), there had been no any abnormal amounts for the other tumor markers. With all these current findings, the patient underwent bilateral modified radical mastectomy.

As a result of histopathological evaluation of specimens, mixed type grade-3 mucinous carcinoma of the breast in both breasts was reported. The left axillary lymph nodes were found in only one in left breast. Although estrogen and progesterone receptors were found as positive, c-erbB-2 was found as negative. →



**Figure A-B:** There were radiopaque masses without spicule formation and microcalcifications in mammographic views of both breasts.

## DISCUSSION

Mucinous breast cancer is characterized by abundant mucin-producing glands and a sub-type of invasive breast cancers. It has relatively better prognosis than other types of breast carcinomas. It accounts for about 1-6% of all breast cancers.<sup>1</sup> It is seen as 7% in women over the age of 75 and as 1% in women under the age of 35.<sup>4</sup> Tumor size may vary between 0.5 cm and 20 cm. Histopathologically, according to the mucin content of the tumor, it is divided into two sub-groups as pure mucinous carcinoma and mixed mucinous carcinoma. Pure mucinous carcinoma has a better prognosis than mixed mucinous carcinoma. In addition, the rate of axillary lymph node metastasis is lower than mixed mucinous carcinoma.<sup>4,7</sup> Radiologically, mucinous breast cancers have findings as well-circumscribed, round or oval-shaped mass. Lobulated contour is a common manifestation of it. One-third of the mucinous breast cancers are monitored by USG as masses in the form of cystic and solid components. While pure mucinous cancers are seen as isoechoic or hypoechoic well-circumscribed homogeneous masses over against environmental fatty tissue, mixed mucinous cancers are often seen as the shape of heterogeneous masses.<sup>5</sup> It can be mixed up with fibroadenoma by ultrasonography and it is often helpful for the differential diagnosis that mucinous cancer is often isoechoic. The breast masses including mucin that have ill-defined margins in mammography conjure up mixed type mucinous tumors. Calcification is a rare finding in mixed type mucinous cancers. Mucinous breast cancers have their own unique MR imaging because of the high mucin content. Secondary to the high content of mucin, it is seen as hyperintense on T2-weighted sequences and iso

or hypointense over against parenchyma on T1-weighted sequences.<sup>6</sup> The contrast retention pattern of mucinous breast cancers may vary. The contrast enhancement kinetics of mucinous tumors which depend on the contrast involvement in only the solid parts of mucinous tumor may resemble benign lesions.<sup>8</sup>

Although the prevailing surgical treatments for mucinous breast cancers are modified radical mastectomy and axillary dissection, adjuvant radiotherapy after lumpectomy and axillary dissection was also performed in the literature.<sup>7</sup> In our case, we performed bilateral modified radical mastectomy by taking into consideration of the patient's general condition and approval of the patient. Because of histopathological report was mixed type and the patient desired to do so, we performed bilateral modified radical mastectomy. Since only one case was reported in the literature as bilateral synchronous mucinous breast cancer, there is still not a clear treatment consensus for the planning of surgical treatment. Thus, treatment planning is open to debate. Macroscopically; it has a soft consistent and well-limited margins, and cross-sectional surface of the tumor has a shiny gelatinous appearance. Due to being well-limited, it can clinically radiologically and macroscopically mimic benign breast lesions. Histopathologically, small cell islands consisting of small uniform cells floating in wide lakes of extracellular mucin and glandular structures are seen. Hormone receptors are usually positive, HER2/neu (human epidermal growth factor receptor 2) is negative. Beside, the breast tumor markers has no place in mucinous breast cancer but they are only used for follow-up.

Consequently, mucinous breast cancer whose ultrasonographic and mammographic appearance vary depending on the amount of mucin and the histopathological type, is a different type of invasive breast carcinoma. Although mucinous breast cancers are rare, they have to be considered in order to assess the other breast in case they are synchronised together. Bilateral mucinous cancer of the breast in premenopausal female has been presented that is first case in literature but it has been reported second case in the literature in postmenopausal women.

<b>C</b>	<b>CORRESPONDING AUTHOR:</b> Hakan Buluş Ankara Keçiören Eğitim Araştırma Hastanesi, Genel Cerrahi, Keçiören 06350 Ankara, Turkey <a href="mailto:hakan_bulus6@hotmail.com">hakan_bulus6@hotmail.com</a>
<b>✓</b>	<b>DELIVERING DATE:</b> 30 / 08 / 2012 • <b>ACCEPTED DATE:</b> 11 / 12 / 2013

## REFERENCES

1. Andre S, Cunha F, Bernardo M, et al. Mucinous carcinoma of the breast: a pathologic study of 82 cases. *J Surg Oncol* 1995; 58: 162-167.
2. Cardenosa G, Doudna C, Eklund GW. Mucinous (colloid) breast cancer: clinical and mammographic findings in 10 patients. *AJR m J Roentgenol* 1994; 162: 1077-1079.
3. Chaudary MA, Millis RR, Hoskins EO, et al. Bilateral primary breast cancer: a prospective study of disease incidence. *Br J Surg* 1984; 71: 711-714.
4. Lam WW, Chu WC, Tse GM, Ma TK. Sonographic appearance of mucinous carcinoma of the breast. *AJR Am J Roentgenol* 2004; 182: 1069-1074.
5. Carmichael AR, Bendall S, Lockerbie L, Prescott R, Bates T. The long-term outcome of synchronous bilateral breast cancer is worse than metachronous or unilateral tumours. *Eur J Surg Oncol* 2002; 28:388-391.
6. Okafuji T, Yabuuchi H, Sakai S, et al. MR imaging features of pure mucinous carcinoma of the breast. *Eur J Radiol* 2006; 60: 405-413.
7. Wilson TE, Helvie MA, Oberman HA, Joynt LK. Pure and mixed mucinous carcinoma of the breast: pathologic basis for differences in amnographic appearance. *AJR Am J Roentgenol* 1995; 165: 285-289.
8. Monzawa S, Yokokawa M, Sakuma T, et al. Mucinous carcinoma of the breast: MRI features of pure and mixed forms with histopathologic correlation. *AJR Am J Roentgenol* 2009; 192: 125-131.