

# NECROTIZING BRUCELLA EPIDIDYMOORCHITIS: MAGNETIC RESONANCE IMAGING FINDINGS

Mehmet Beyazal, Sercan Özkaçmaz, Özkan Ünal, Alpaslan Yavuz, Aydın Bora

Yüzüncü Yıl University, School of Medicine, Department of Radiology, Van, Turkey

## ABSTRACT

*Brucella epididymoorchitis (BEO) had been reported up to 20% of patients with brucellosis. Although it has a good response to specific antibiotherapy, the delay in diagnosis and in treatment may result in necrosis and abscess formation. Ultrasonography is the basic imaging method for screening of scrotal diseases such as BEO. In literature, there are many studies which present sonographic and magnetic resonance imaging (MRI) features of scrotal*

*and testicular lesions. However, there is no any sufficient publication in which the findings of BEO have been defined on MRI examination. In this report, we presented a patient who had unilateral necrotizing epididymoorchitis and testicular abscess resulted from brucellosis with MRI findings and we also discussed the contribution of MRI to the management of the disease.*

**Key Words:** Brucellosis, epididymoorchitis, MRI. *Nobel Med 2014; 10(2): 88-91*

## NEKROTİZAN BRUCELLA EPİDİDİMOORŞİTİ: MANYETİK REZONANS GÖRÜNTÜLEME BULGULARI

### ÖZET

Brusella epididimoorşiti brusellozlu hastaların %20'sinde rapor edilmiştir. Spesifik antibiyotik tedavisine iyi yanıt verir ancak gecikmiş tedavi nekroz ve apse formasyonu ile sonuçlanır. Brusella epididimoorşiti (BEO) yanısıra skrotal hastalıklarının değerlendirilmesinde ultrasonografi stan-

dart görüntüleme tekniğidir. Literatürde skrotum ve testis lezyonlarının ultrasonografi ile birlikte manyetik rezonans görüntüleme (MRG) bulgularında tanımlanmıştır. BEO'nin MRG bulgularından yeterince bahseden yayın bulunmamaktadır. Biz bu yazıda brusellanın neden olduğu tek taraflı nekrotizan epididimoorşit ve testiküler apseli olguyu, MRG bulguları ile birlikte sunduk ve MRG'nin hasta yönetimine olan katkısını değerlendirdik.

**Anahtar Kelimeler:** Brusella, epididimoorşit, MRG. *Nobel Med 2014; 10(2): 88-91*

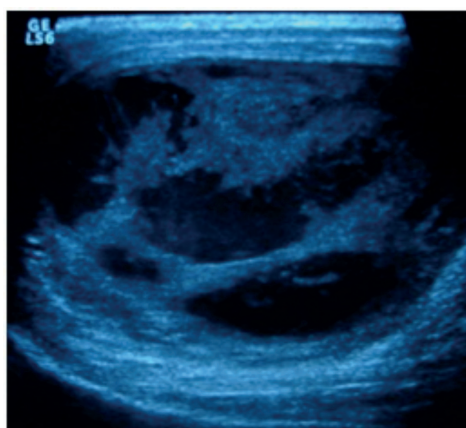
## INTRODUCTION

Brucellosis is a well known zoonotic disease. Consumption of unpasteurised milk and milk products is a common mode of transmission of *Brucella* spp. to humans. Rare modes of transmission include transplacental transfer, breast feeding, respiratory and even sexual intercourse.<sup>1</sup> The complications which may develop during the acute or chronic stages affect bones and joints, cardiovascular system, central nervous system, genitourinary tract.<sup>2</sup> *Brucella* epididymo-orchitis (BEO) is a focal complication of the human brucellosis and has been described in 2%-20% of patients with brucellosis.<sup>3</sup>

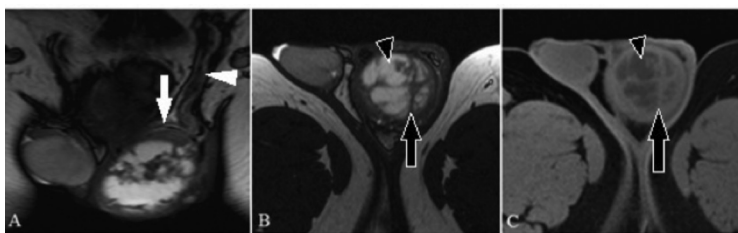
Ultrasound imaging findings of BEO are well established. It manifests as unilateral or bilateral testicular and/or epididymal involvement. Enlargement of the epididym and testis, increased vascularity and low echogenic paranchyma are observed. Thickened scrotal skin and hydrocele can also be seen. These findings may be also detected in the patients with non-specific epididymo-orchitis.<sup>3,4</sup> However, testicular heterogeneity, focal echogenicity differences, presence of granularities and septates in hydrocele are more common in BEO than non-specific orchitis.<sup>4</sup> MRI is superior to the other imaging modalities in evaluating soft tissues. Besides ultrasonographic findings, the magnetic resonance imaging (MRI) findings of benign and malign tumors of scrotum, non-specific epididymo-orchitis and tuberculous epididymo-orchitis have also been described well in the literature but to our knowledge there is not satisfactory case reports associated with MRI features of BEO in literature.<sup>5,6</sup> In this case report, we presented a patient who had unilateral necrotizing epididymo-orchitis and testicular abscess resulted from brucellosis with MRI findings and we also discussed the contribution of MRI to the diagnosis of the disease.

## CASE REPORT

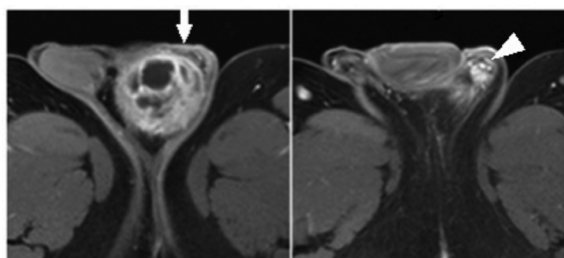
A 34 year old male admitted to clinic with left testicular pain, swelling in the left side of scrotum for approximately 4 weeks duration. One week after his complaints started he had a diagnosis as nonspecific epididymo-orchitis and was treated with conventional antibiotherapy for 10 days. He reported an increase in the swelling of left testicle and thickening of the scrotum skin for the last week. His medical history revealed a mild fatigue but not any voiding or musculoskeletal complaints. Physical examination indicated left testicular swelling and tenderness. Also, left hemiscrotum skin was thickened. Laboratory studies showed a mild leucocytosis ( $11000/\text{mm}^3$ ) with an erythrocyte sedimentation rate of 9 mm/h. Tumor



**Figure 1:** There are cystic-necrotic areas in enlargement testicle. Also thickened skin is seen.



**Figure 2:** Coronal (A), axial (B) T2 and axial (C) T1 weighted images demonstrates the markedly enlargement of left testicle, epididymis (white arrow) and spermatic cord (white arrowhead). Left testicle parenchyma volume was markedly decreased and there are cystic necrotic areas (black arrowhead) and septates (black arrow)



**Figure 3:** Axial postcontrast T1-weighted images demonstrates increased contrast enhancement of left peritesticular tissue, adjacent skin (white arrow), left spermatic cord (white arrowhead) and septates in testicle.

markers of testicular carcinoma (Alpha-fetoprotein and Human chorionic gonadotropin) were found to be within the normal limits and urinalysis was normal. *Brucella* spot and Wright agglutination tests were performed and each of them were found to be positive (Wright agglutination test in a titer of 1/640). Wright agglutination test performed after administration of 2-mercaptoethanol was positive with the titer of 1/160. Blood cultures were negative.

Ultrasonography showed large cystic-necrotic areas in enlarged heterogeneous left testicle. Also left hemiscrotum skin was thickened (Figure 1). MRI was performed to detect extent of testicular parenchyma involvement and destruction. MRI showed obviously the enlargement and decreased total parenchymal volume of left testicle as well the septates and abscess →

formation within the tissue. Also there is contour irregularity in the left testis and the left spermatic cord was thickened (Figure 2). Postcontrast T1 weighted images demonstrated increased heterogeneous contrast enhancement of the left peritesticular area, epididymis, adjacent skin, spermatic cord and the septates within the testicle (Figure 3).

Relying on these clinical, laboratory and radiologic findings the patient was diagnosed as BEO and regimen composed of rifampicin, tetracycline and ceftriaxone, complete bed rest with scrotal elevation and local hypothermia application was started.<sup>7-9</sup> Because of the total paranchymal loss and abscess formation, the surgical treatment with left orchiectomy was recommended to the patient but he refused it. At the 10 day-follow-up, there was a clinical improvement, but no any significant difference was observed in the extend of testicular abscess by a ultrasound examination. The medical treatment with anti-brucella antibiotherapy and control were recommended to the patient who refused surgical treatment. However patient did not refer again for follow-up visits.

## DISCUSSION

Brucellosis is a zoonotic systemic bacterial infection which affects most organ systems. Brucellosis remains an important clinical problem worldwide, and needs to be highlighted as a continuing cause of morbidity in southern Europe and in many developing countries.<sup>10</sup> Complication of brucellosis involving the genital tract is not rare.<sup>2</sup> Although the prognosis of BEO is usually good, delay in diagnosis or inappropriate management may result in serious complications, such as necrotizing orchitis, testicular abscess, which may require orchiectomy.<sup>11</sup>

Ultrasonography plays an important role in the diagnosis, assessment, and management of patients with BEO. Unilateral epididymoorchitis is the most common genitourinary complication of brucellosis. Infection that is limited to the testis is rare; the epididymis is usually involved in patients who have acute inflammation. Ultrasonographic characteristics are enlargement, a hypoechoic echotexture of the epididymis and testis, the presence of a hydrocele, and thickening of scrotal skin. In normal epididymis, very few or no vessels are seen on color Doppler sonograms, but the size and number of vessels increase if the epididymis is inflamed. The changes seen on color Doppler images may precede changes evident on gray-scale sonograms.<sup>12</sup> Ultrasonography discloses diffuse enlargement of the testis with several well-defined irregular hypoechoic areas. Granulomatous inflammation can be associated

with focal necrotic areas.<sup>12</sup> Necrotizing orchitis is a rare form of Brucella infection that must be distinguished from necrotizing involvement arising from other pathogens (Mycobacterium tuberculosis or Salmonella species).<sup>3</sup> Ozturk et al. reported that heterogeneity, focal echogenicity differences and hydrocele with granularity and/or septation seen in a patient presenting with scrotal infection in brucella endemic areas must rise the possibility of brucellosis rather than non-specific epididymoorchitis.<sup>4</sup>

Although sonography is the standard imaging technique for the investigation of scrotal masses, MRI may represent an efficient supplemental technique owing to its wide field of view, multiplanar capabilities and intrinsic high soft tissue contrast, permitting accurate localization of scrotal lesions and evaluation of the relationship between the lesions and testicular tunicae.<sup>5</sup> At MRI, non-specific epididymoorchitis generally demonstrates heterogeneous areas of low signal intensity on T2-weighted images. The epididymis may be enlarged and hyperenhancing on contrast enhanced T1-weighted images. Inhomogeneous enhancement of the testis with hypointense bands may also be seen.<sup>6</sup> Abscess formation can complicate orchitis. The formation of abscess results in fluid collections between the testicular septations, which are seen as areas of very high signal intensity on T2-weighted image.<sup>13</sup>

Granulomatous orchitis deserves special mention because it often has a more indolent course and can also manifest as a testicular mass. Multiple pathogens including tuberculosis, syphilis, fungi, and parasites may cause a granulomatous epididymoorchitis. These processes tend to involve the epididymis first and to a much greater extent than the testis.<sup>14</sup>

In our case, epididymoorchitis was accompanied by testicular abscess and necrosis. MRI demonstrated enlargement of the left testicle, epididymis and spermatic cord. The formation of abscess resulted in fluid collections between the testicular septations, which were seen in areas of very high signal intensity on T2-weighted images. On a T1 and T2 weighted images, the left scrotal skin thickening had heterogeneous signal intensity, which was indicative of inflammation. Postcontrast T1 weighted images demonstrated increased heterogeneous contrast enhancement of the left peritesticular area, epididymis, adjacent skin, spermatic cord and the septates within the testicle. In addition to ultrasonography MRI clearly demonstrated the spermatic cord involvement and total testicular paranchymal loss. These findings let us to consider surgical treatment in addition to medical treatment with antibiotherapy at the treatment decision. →

The differential diagnosis of an infiltrative process involving both the epididymis and the testis should include bacterial epididymo-orchitis, tuberculosis, sarcoidosis, lymphoma and leukaemia. Bacterial infection is usually unilateral and it is accompanied by symptoms and clinical findings suggestive of the disease. Involvement of the male reproductive system by sarcoidosis is extremely rare.<sup>5</sup> The disease is usually unilateral and is manifested as a painful nodular mass involving the epididymis. Extension to the testis is extremely rare, being reported in 1% of cases.<sup>15</sup> Leukaemia, on the other hand, may manifest as an infiltrative epididymal, testicular mass, but often involves patients with a prior history of treated leukaemia. Lymphoma, although representing 1-9%

of all testicular tumours, it is the most common malignancy in men over the age of 60 years.<sup>5</sup>

Delayed diagnosis and inappropriate management can cause severe results such as abscess and necrosis that can lead to aspermia, infertility. Especially, in endemic regions, all patients with brucella seropositivity who have scrotal complaints must be evaluated with detailed radiological examinations including ultrasonography and also MRI. It must be kept in mind that MRI can provide important information for detection of complication and extend of parenchymal involvement in BEO.

\* The authors declare that there are no conflicts of interest.



<b>C</b>	<b>CORRESPONDING AUTHOR:</b> Mehmet Beyazal Yüzüncü Yıl Üniversitesi Tıp Fakültesi, Radyoloji AD. Van, TÜRKİYE drbeyazal@hotmail.com
<b>✓</b>	<b>DELIVERING DATE:</b> 30 / 11 / 2012 • <b>ACCEPTED DATE:</b> 16 / 12 / 2013

## REFERENCES

1. Kulkarni RD, Chunchanur SK, Ajantha GS, Shubhada C, Jain P. Presumptive diagnosis of brucella epididymo-orchitis by modified cold ZN staining of testicular pus sample. *Indian J Med Res* 2009; 130: 484-486.
2. Mantur BG, Mulimani MS, Mangalgi SS, Patil AV. Brucellar epididymo-orchitis -report of five cases. *Indian J Med Microbiol* 2001; 19: 208-211.
3. Navarro-martinez A, Sloera J, Corredoira J, et al. Epididymo-orchitis Due To Brucella melitensis: A Retrospective Study of 59 Patients. *Clin Infect Dis* 2001; 33: 2017-2022.
4. Ozturk A, Ozturk E, Zeyrek F, et al. Comparison of brucella and non-specific epididymo-orchitis: gray scale and color Doppler ultrasonographic features. *Eur J Radiol* 2005; 56: 256-262.
5. Tsili AC, Tsampoulas C, Giannakis D, et al. Tuberculous epididymo-orchitis: MRI findings. *Br J Radiol* 2008; 81: 166-169.
6. Kim W, Rosen MA, Langer JE, et al. US-MR imaging correlation in pathologic conditions of the scrotum. *Radiographics* 2007; 27: 1239-1253.
7. Al-Idrissi HY, Uwaydah AK, Danso KT, Qutub H, Al-Mousa MS. Ceftriaxone in the treatment of acute and subacute human brucellosis. *J Int Med Res* 1989; 17: 363-368.
8. Bodur H, Erbay A, Akinci E, et al. Neurobrucellosis in an endemic area of brucellosis. *Scand J Infect Dis* 2003; 35: 94-97.
9. Tekin-Koruk S, Duygu F, Gursoy B, Karaağac L, Bayraktar M. A rare case of seronegative neurobrucellosis. *Ann Saudi Med* 2010; 30: 412-414.
10. Coşkun Ö, Gül HC, Mert G, et al. Brucellar Epididymo-Orchitis: A Retrospective Study. *Trakya Univ Tıp Fak Derg* 2009; 26: 220-225.
11. Yurdakul T, Sert U, Acar A, Karalezli G, Akcetin Z. Epididymo-orchitis as a complication of brucellosis. *Urol In* 1995; 55: 141-142.
12. Patel PJ, Kolawole TM, Sharma N, et al. Sonographic findings in scrotal brucellosis. *J Clin Ultrasound* 1988; 16: 483-486.
13. Cramer BM, Schlegel EA, Thueroff JW. MR imaging in the differential diagnosis of scrotal and testicular disease. *Radiographics* 1991; 11: 9-21.
14. Woodward PJ, Sohaey R, O'Donoghue MJ, Green DE. From the archives of the AFIP: tumors and tumorlike lesions of the testis: radiologic-pathologic correlation. *Radiographics* 2002; 22: 189-216.
15. Kodama K, Hasegawa T, Egawa M, et al. Bilateral epididymal sarcoidosis presenting without radiographic evidence of intrathoracic lesion: review of sarcoidosis involving the male reproductive tract. *Int J Urol* 2004; 11: 345-348.