

PITUITARY ADRENAL INSUFFICIENCY IN A CANCER PATIENT UNDER OPIOID TREATMENT

Fatma Avcı Merdin¹, Alparslan Merdin¹, Melek Karakurt Eryılmaz², Safiye Arık³, Şeyda Gündüz², Hasan Şenol Coşkun², Hasan Altunbaş³

¹Akdeniz University Hospital, Department of Internal Medicine, Antalya

²Akdeniz University Hospital, Division of Medical Oncology, Antalya

³Akdeniz University Hospital, Division of Endocrinology and Metabolism, Antalya

ABSTRACT

Opioid induced suppression of the hypothalamic-pituitary-adrenal axis is rare and mostly misdiagnosed in clinical handling. Weakness and debility are nonspecific symptoms that are seen in chronic cancer patients. Here, we report a case of adrenal crisis in a patient using opioid for malignancy related pain. A 65 year-old woman with lung and anorectum cancer had been referred to our hospital. She had been under 15 days of opioid therapy because of bone metastasis related cancer pain. She complained of back pain, weakness, weight loss, fatigue and hypotension. The patient was evaluated with suspected adrenal

insufficiency. She had adrenocortical and pituitary insufficiency with adrenal crisis. Plasma ACTH and cortisol levels were detected low. Pituitary failure was diagnosed and hypophysis MRI showed reduced hypophysis volume (diameter) without heterogeneity; hypophysis height was stated as 4 mm. Prednisolone treatment was started and the patient's symptoms and complaints improved. These symptoms might be attributed to an underlying malignant disease, but one should always keep in mind adrenocortical insufficiency in case of chronic high-dose opioid usage.

Key Words: Opioid treatment, adrenal insufficiency, malignancy

OPIOİD TEDAVİSİ ALTINDAKİ BİR KANSER HASTASINDA GÖRÜLEN PİTÜİTAR ADRENAL YETERSİZLİK OLGUSU

ÖZET

Opioid kullanımına bağlı hipotalamo-hipofizer-adrenal aksın baskılanması nadir görülen bir durumdur ve genellikle klinik olarak gözden kaçmaktadır. Kanser hastalarında halsizlik ve güçsüzlük sık görülen nonspesifik semptomlardır. Burada maligniteye bağlı ağrı nedeniyle opioid tedavisi almakta iken, adrenal yetersizlik tablosu görülen bir olgu sunulmuştur. Multiple primerli anorektum ve akciğer kanseri tanılı, 65 yaşındaki kadın hasta yaygın kemik metastazlarına bağlı ağrı nedeniyle 15 gündür opioid türevi analjezik tedavisi almaktaydı. Sırt ağrısı, halsizlik, yorgunluk,

kilo kaybı olan ve hipotansif seyreden hastada, yapılan tetkikler sonucunda ACTH ve kortizol düzeyleri düşük bulundu. Hipofizer adrenokortikal yetersizlikten şüphelenilen hastada etiyojiye yönelik yapılan hipofizer görüntüleme, hipofiz parankimi heterojenitesi azalmış olup koronal uzunluğu 4 mm olarak ölçüldü. Hastaya metilprednizolon tedavisi başlandı ve takibinde semptomları düzeldi. Halsizlik, yorgunluk, kilo kaybı, hipotansiyon ve sırt ağrısı gibi nonspesifik semptomlar, kanser hastalarında da ortaya çıkabilen nonspesifik semptomlar olmakla birlikte; opioid türevi analjezik kullanan kanser hastalarında ise bu semptomlar varlığında adrenokortikal yetersizlik görülebileceği göz ardı edilmemelidir.

Anahtar Kelimeler: Opioid tedavisi, adrenal yetersizlik, malignite

INTRODUCTION

Adrenal insufficiency is caused by either primary adrenal failure or by hypothalamic-pituitary impairment of the corticotrophic axis. The main presenting symptoms including weight loss, hypotension, fatigue and anorexia are nonspecific, and thus diagnosis is often delayed.¹ Rapidly stopping exogenous steroid treatment is the most common cause of adrenal insufficiency. Literature analysis has shown that some infections and drugs, including aminoglutethimide, ketoconazole, megestrol acetate, metyrapone and mitotane can result in secondary adrenocortical insufficiency.² Chronic malignant pain is often managed by using opioid medications. It is currently known that opioids also have detrimental effects on the endocrine system, including hypothalamic-pituitary-adrenal (HPA) axis.^{3,4} The mechanisms underlying this interference are unknown, but it is possible that opioids inhibit HPA axis through μ -opiate receptor.⁵

Endogenous and exogenous opioids exert an inhibitory effect on GnRH.⁶ Opioids decrease luteinizing hormone (LH), while opiate antagonists (e.g., naloxone hydrochloride) increase these hormone levels.⁷ Daily use of opioids for the treatment of chronic pain has also been demonstrated to cause a dose-related decrease in adrenal androgen production measured by DHEAS levels.⁸ Suppression of the HPA axis is not usually taken into consideration during treatment with chronic high-dose opiate medication in clinical handling. Here, we present a patient diagnosed with adrenal crisis during the course of high dose opioid usage.

CASE

A 65 year-old woman was referred to Emergency Department of Akdeniz University Hospital with complaints of back pain, weakness, weight loss, fatigue and hypotension. The patient had two primaries of lung and anorectal cancer. She had been diagnosed with anorectal cancer five years earlier. She developed lung cancer as the second primary while she was on follow-up in remission for anorectal cancer. She had only bone metastases and was receiving chemotherapy (docetaxel, cisplatin). On admission, her body temperature was 36.9°C, blood pressure 80/50 mmHg, pulse 90/min and respiratory rate 20/min. Her systemic and neurologic examinations were unremarkable. Laboratory parameters were as follows: Hemoglobin: 10 g/dl (12-16 gr/dl), C-reactive protein: 8.3 mg/dl (0-0.5 mg/dl), WBC (white blood cells): 9870/mm³ (4800-10800/mm³), sodium: 130 mEq/L (136-145 mEq/L),

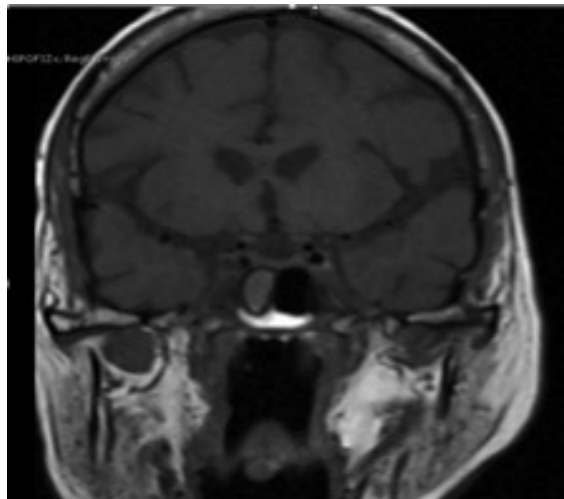


Figure 1: Hypophysis height is stated as 4 mm. There is retention cyst in the right sphenoid sinus.

potassium: 4.8 mEq/L (3.5-5.1 mEq/L) and procalcitonin: 0.1 ng/ml (0-0.5 ng/ml). There was no sign or symptoms of an infectious diseases. Blood and urine cultures were sterile. We looked for thyroid and adrenal hormone levels to exclude hypothyroidism and adrenal insufficiency, in accordance with the clinical findings.

Her TSH (thyroid stimulating hormone) level was 0.9 μ IU/mL (0.2-4.2), free T4 level 1.7 pg/mL (0.2-1.56), ACTH (adrenocorticotrophic hormone) level 1 pg/ml (0-65 pg/ml) and cortisol level 1.16 ug/dl (4.3-22.4 ug/dl). She was diagnosed with secondary adrenocortical insufficiency. Plasma FSH (follicle stimulating hormone) level was 0.1 mIU/mL (1.5-12.4 mIU/mL), LH level 0.2 mIU/mL (1.7-8.6 mIU/mL), estradiol level 37.4 pg/mL (24-195 pg/mL) and GH (growth hormone) level was 1 ng/ml (0-8 ng/ml) to exclude pituitary failure. Pituitary failure was diagnosed and hypophysis MRI showed lower limit of normal hypophysis volume (diameter) without heterogeneity; hypophysis height was stated as 4 mm (Figure 1).

She had been under tramadol 200 mg and transdermal phentanyl 25-50 mcg treatment for 15 days to reveal her chronic malignant pain. She denied using other drugs that could affect pituitary function. She had regular menses before menopause. Therefore, we suspected opiate-induced suppression of the HPA axis. Exogenous steroid was started and the patient's complaints and symptoms quickly disappeared.

DISCUSSION

Opioids induce a wide spectrum of endocrinopathies like decrement in testosterone, LH, FSH and cortisol levels. Our patient had pituitary and adrenal failure. She did not use any other drugs interfering with HPA axis, except opioids. She had her menstrual

→
**PITUITARY ADRENAL
INSUFFICIENCY IN
A CANCER PATIENT
UNDER OPIOID
TREATMENT**

cycles until she reached menopause, therefore, we also excluded the Sheehan's Syndrome. Her hypophysis was a little small at MRI (coronal view). Pituitary height was lower limit of normal. This decreased diameter together with pituitary failure may suggest previous hypophysitis. She had no history of any radiotherapy or trauma. An autoimmune etiology (lymphocytic hypophysitis) might have been responsible for that condition. Lymphocytic hypophysitis seemed to be strongly correlated with pregnancy, especially in the first large series of patients reported in the literature.^{9,10} Our patient had neither any autoimmune diseases, nor a recent pregnancy. However, it is also possible that opioid usage may have triggered the hypothalamic-pituitary-adrenal failure.

Opioid-induced endocrinopathies are one of the most

common yet least often diagnosed consequences of prolonged opioid therapy.⁶ Opioid usage can be a cause of adrenal insufficiency, but also can trigger adrenal insufficiency. There is not much data in the literature about this issue. To our knowledge, there are only two cases of adrenal crisis secondary to chronic opioid usage in the literature.^{11,12} As far as we know, there is only one case of an adrenal crisis secondary to chronic opioid usage for malignant pain in the literature.¹¹ Weakness and debility are common symptoms in chronic cancer patients using opioids. These symptoms may be attributed to an underlying malignant disease, but one should always keep in mind adrenocortical insufficiency in cases of chronic high-dose opioid usage. With according to this, opiates should be added to the list of differential diagnoses in patients with newly diagnosed with secondary adrenal insufficiency.

C	CORRESPONDING AUTHOR: Fatma Avcı Merdin Dumlupınar Bulvarı, Akdeniz Üniversitesi Hast., İç Hastalıkları Anabilim Dalı, 07059, Kampüs Antalya, Türkiye E-mail: fatma_avci.md@hotmail.com
✓	DELIVERING DATE: 21 / 05 / 2014 • ACCEPTED DATE: 12 / 08 / 2014

REFERENCES

1. Arlt W, Allolio B. Adrenal insufficiency. *Lancet* 2003; 361: 1881-1893.
2. Stewart PM. The Adrenal Cortex. In: Kronenberg HM, Shlomo M, Polonsky KS, Larsen PR, eds. *Williams Textbook of Endocrinology*. 11th ed. Philadelphia, Pa: Saunders Elsevier; 2008: chap 14.
3. Vuong C1, Van Uum SH, O'Dell LE, Lutfy K, Friedman TC. The effects of opioids and opioid analogs on animal and human endocrine systems. *Endocr Rev* 2010; 31: 98-132.
4. Abs R, Verhelst J, Maeyaert J, et al. Endocrine Consequences of Long-Term Intratecal Administration of Opioids. *J Clin Endocrinol Metab* 2000; 85: 2215-2222.
5. Ducat E, Ray B, Bart G, et al. Mu-opioid receptor A118G polymorphism in healthy volunteers affects hypothalamic-pituitary-adrenal axis adrenocorticotrophic hormone stress response to metyrapone. *Addict Biol* 2013; 18: 325-331.
6. Colameco S, Coren JS. Opioid-Induced Endocrinopathy. *J Am Osteopath Assoc* 2009; 109: 20-25.
7. Mendelson JH, Ellingboe J, Kuehnle JC, Mello NK. Heroin and naltrexone effects on pituitary-gonadal hormones in man: interaction of steroid feedback effects, tolerance and supersensitivity. *J Pharmacol Exp Ther* 1980; 214: 503-506.
8. Daniell HW. DHEAS deficiency during consumption of sustained-action prescribed opioids: evidence for opioid-induced inhibition of adrenal androgen production. *J Pain* 2006; 7: 901-907.
9. Hashimoto K, Takao T, Makino S. Lymphocytic adenohypophysitis and lymphocytic infundibuloneurohypophysitis. *Endocr J* 1997; 44: 1-10.
10. Beressi N, Beressi JP, Cohen R, Modigliani E. Lymphocytic hypophysitis. A review of 145 cases. *Ann Med Intern* 1999; 150: 327-341.
11. Oltmanns KM, Fehm HL, Peters A. Chronic fentanyl application induces adrenocortical insufficiency. *J Intern Med* 2005; 257: 478-480.
12. Schimke KE, Greminger P, Brändle M. Secondary adrenal insufficiency due to opiate therapy - another differential diagnosis worth consideration. *Exp Clin Endocrinol Diabetes* 2009; 117: 649-651.