

A CLINICALLY SILENT PHEOCHROMOCYTOMA COMBINED WITH SUBCLINICAL CUSHING'S SYNDROME IN THE SAME ADRENAL GLAND: A CASE REPORT AND REVIEW OF LITERATURE

Cihangir Erem¹, Nadim Civan¹, Mehmet Fidan¹, Ümit Çobanoğlu², Fevzi Kangül¹, Hülya Coşkun¹, İdris Yıldız¹

¹Karadeniz Technical University Faculty of Medicine, Department of Internal Medicine, Division of Endocrinology and Metablism, Trabzon

²Karadeniz Technical University Faculty of Medicine, Department of Internal Medicine, Department of Pathology, Trabzon

ABSTRACT

Objective: The coexistence of silent pheochromocytoma (PHEO) and subclinical Cushing's syndrome (SCS) of the same adrenal gland has not been reported in the English literature.

Case: We describe an adult case of clinically silent PHEO combined with SCS incidentally diagnosed by abdominal ultrasonography in a 51-year-old female patient. Physical examination revealed that her blood pressure (BP) and tension Holter monitoring were normal. Computed tomography and magnetic resonance imaging showed a solid tumor (3.5×3.0×2.5 cm) in the right adrenal gland, consistent with a nonadenomatous mass. Urinary levels of catecholamines and their metabolites were elevated. SCS was suggested by the failure to obtain adequate cortisol suppression (less than 1.8 µg/dl) following dexamethasone administration in single-dose 1-mg overnight dexamethasone suppression test (DST) and low-dose 2-mg DST. Right adrenalectomy was performed for treatment purposes. The histological diagnosis of

the resected tumor was typical adrenal PHEO with adrenocortical hyperplasia.

Conclusion: Pheochromocytoma combined with SCS in the same adrenal gland is a rare entity and preoperative diagnosis of these combined tumors is difficult. Its hormonal activity and imaging characteristics are frequently very similar to those of other adrenal tumors, especially pure PHEO. Therefore, careful evaluation by endocrine tests and multiple imaging procedures are needed to provide a differential diagnosis. However, definitive diagnosis is established by histological and immunohistochemical studies. To our knowledge, the present case is the first case report that describes clinically silent PHEO combined with SCS in the same adrenal gland in the English literature. We discuss this case and review the literature on this unusual entity.

Keywords: Corticomedullary mixed adrenal tumor, silent pheochromocytoma, subclinical Cushing's syndrome, incidentaloma. *Nobel Med* 2017; 13(1): 74-80

AYNI ADRENAL BEZDE KLİNİK OLARAK SESSİZ FEOKROMOSİTOMA İLE KOMBİNE SUBKLİNİK CUSHING SENDROMU: BİR VAKA SUNUMU VE LİTERATÜRÜN GÖZDEN GEÇİRİLMESİ

ÖZET

Amaç: İngilizce literatürde aynı adrenal bezde sessiz feokromositoma (FEO) ve subklinik Cushing sendromu (SCS) birlikteliği bildirilmemiştir.

Olgu: Biz 51 yaşındaki bir kadın hastada karın ultrasonografisinde insidental olarak saptanan ve klinik olarak SCS ile kombine sessiz FEO olgusunu sunuyoruz. Fizik muayenede kan basıncı ve tansiyon Holter takibi normaldi. Bilgisayarlı tomografi ve manyetik rezonans görüntüleme sağ adrenal bezde adenom dışı kitle ile uyumlu solid bir tümör (3,5×3,0×2,5 cm) görüldü. İdrarda katekolamin ve metabolit değerleri yüksekti. SCS varlığı gece tek doz 1-mg deksametazon (DXT) supresyon testi (DST) ve düşük doz 2-mg DST’nde kortizol düzeyinin suprese

olmaması ile gösterildi. Tedavi amaçlı olarak hastaya sağ adrenalektomi yapıldı. Rezeksiyon yapılan tümörün histolojik tanısı adrenokortikal hiperplaziye eşlik eden tipik adrenal FEO olarak kondu.

Sonuç: Aynı adrenal bezde SCS ile kombine FEO nadir bir durumdur ve bu tümörlerin preoperatif tanısı zordur. Hormonal aktivite ve görüntüleme özellikleri sık olarak diğer adrenal tümörlere ve FEO’ya benzer. Bu nedenle ayırıcı tanıda endokrin testlerin ve multipl görüntüleme yöntemleri ile dikkatli değerlendirmeye ihtiyaç vardır. Bununla birlikte, kesin tanı histolojik inceleme ve immünohistokimyasal çalışmalar ile konur. Bizim bilgimize göre bu hasta İngilizce literatürde aynı adrenal bezde SCS ile kombine klinik olarak sessiz FEO’yı tanımlayan ilk vaka bildirimidir. Nadir görülen bu vaka tartışılarak mevcut literatür gözden geçirildi.

Anahtar kelimeler: Kortikomedüller mikst adrenal tümör, sessiz feokromositoma, subklinik Cushing sendromu, insidentaloma. **Nobel Med 2017; 13(1): 74-80**

INTRODUCTION

Adrenal incidentalomas (AIs) are discovered inadvertently in the course of work-up or treatment of unrelated disorders.^{1,2} In radiological studies, the frequency of AIs ranges from approximately 4% in middle age and to over 10% in the elderly.^{2,3} About 85% of AIs are nonfunctional masses, 4-9% are defined as pheochromocytoma (PHEO) and 9% are subclinical Cushing’s syndrome (SCS).^{1,2,4,5}

Pheochromocytomas are rare catecholamine-secreting neuroendocrine tumor arising from chromaffin cells of the adrenal medulla or extra-adrenal sites.^{2,6,7} The prevalence of PHEO in hypertensive patients is 0.1-0.6%.^{8,9} Because of excess secretion of the hormones epinephrine (E), norepinephrine (NE), dopamine, and others, patients with PHEO often experience symptomatic attacks characterised by severe hypertension, profuse sweating, palpitations, and headaches.^{1,7} Approximately 10% of histologically proven benign PHEOs are incidentally discovered by radiologic imaging procedures in the absence of symptoms.^{9,10} Of the adrenal PHEO, 20% to 30% of them are asymptomatic; they are called clinically silent PHEO.^{9,11-18} In these cases, there is no classic triad of the disease (episodic headache, sweating, and palpitation) at presentation (normotensive PHEO)^{10,11} Moreover, up to 50% of patients with an incidental adrenal PHEO are normotensive.^{1,19}

Subclinical Cushing’s syndrome (SCS) represents autonomous cortisol secretion in patients who do not have the typical signs and symptoms of endogenous clinical CS.²⁰⁻²² The criteria for the diagnosis of SCS are not well defined.²⁰ Different biochemical changes in the hypothalamo-pituitary-adrenal axis have been found in these patients: altered dexamethasone (DXT) suppression test (DST), low adrenocorticotrophic hormone (ACTH) level, normal/or increased urinary free cortisol (UFC) secretion and a reduction in dehydroepiandrosterone sulfate (DHEAS).^{22,23} The DST (cutoff of 3.0µg/dl)-UFC-ACTH combination criterion seems to be the best compromise to diagnose SCS because it has been validated on a clinical basis.^{22,24}

Pheochromocytoma combined with SCS in the same adrenal gland is extremely rare. To date, only 8 cases have been reported in the English literature.^{4,20,21,25-29} It is difficult to diagnose these tumors precisely as adrenal PHEO combined with SCS before surgery. Definitive diagnosis is done by histological examination. To our knowledge, the coexistence of clinically silent PHEO and primary SCS of the same adrenal gland has not been reported in the English literature. In this report, we firstly present a case of coexistence of both tumors incidentally diagnosed in a 51-year-old female patient. Histopathological examination of the adrenal mass confirmed the diagnosis.

A CLINICALLY SILENT PHEOCHROMOCYTOMA COMBINED WITH SUBCLINICAL CUSHING’S SYNDROME IN THE SAME ADRENAL GLAND: A CASE REPORT AND REVIEW OF LITERATURE

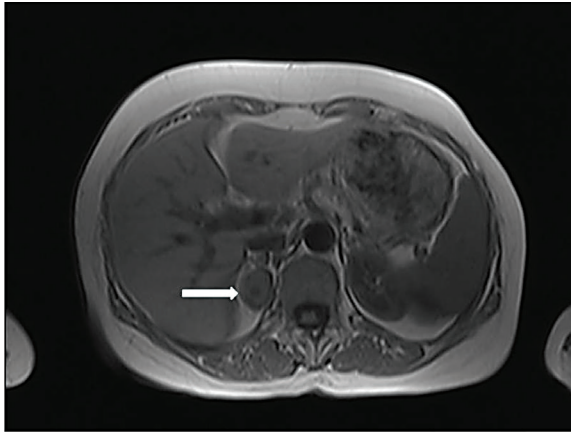


Figure 1. (A) Transverse T1-weighted MRI shows a round right adrenal mass that measures 3.5×3.0×2.5 cm (arrow). The mass is heterogeneous, with signal intensity less than that of liver (hypointense).

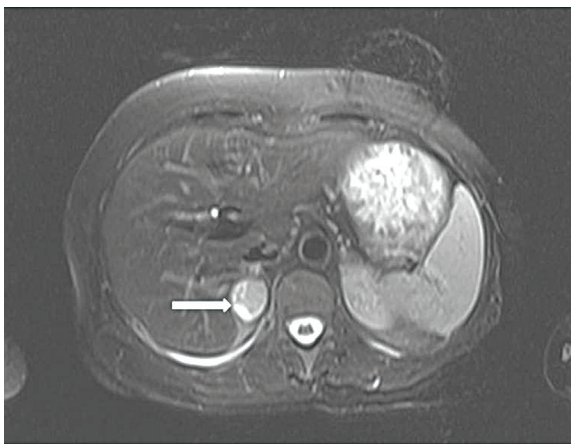


Figure 1. (B) Transverse T₂-weighted MRI scan demonstrating round heterogeneous right adrenal mass (arrow) with markedly high signal intensity greater than that of liver (prominently hyperintense)

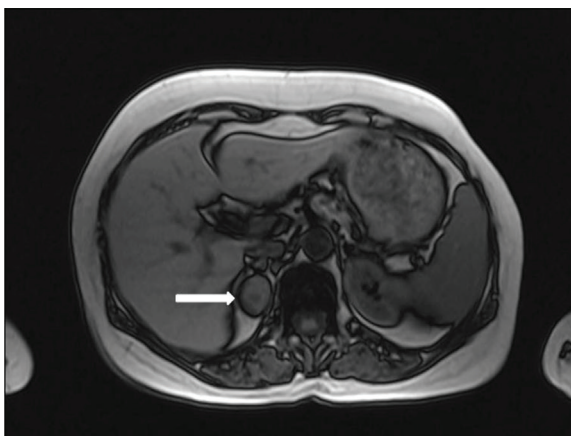


Figure 1. (C) Out-of-phase MRI no showing significant signal loss in the lesion when compared with in-phase MRI (arrow).

CASE REPORT

A 51-year-old Turkish woman was hospitalized at our hospital for further examinations of a heterogeneous, hypoechogenic right adrenal solid mass, measuring

3.5×3.0 cm, with well-defined borders that was incidentally discovered by abdominal US during urinary tract infection research in another hospital. She did not have any complaints of episodic headaches, sweating, palpitation, chest pain, or hypertension. There was no history of weight gain. On physical examination (PE), she had a blood pressure (BP) of 110/70 mmHg without postural drop, a regular pulse of 72 beats/min, and a weight of 64.3 kg at a height of 164 cm. Body mass index was 23.9 kg/m². The patient displayed discrete Cushing's stigmata with slight moon facies, plethora, and abdominal obesity, but there was no evidence of hirsutism, acne, purple abdominal stria, acanthosis nigricans, or mucosal hyperpigmentation. The remainder of PE, which included a fundoscopy, was normal. Tension Holter monitoring was normal (maximum systolic BP of 135 mmHg and maximum diastolic BP of 86 mmHg). No abnormalities were noted in the electrocardiography or chest X-ray. Echocardiography showed left ventricle hypertrophy in borderline (interventricular thickness, 12 mm) and diastolic dysfunction. Routine haemogram, urine examination, liver and kidney function tests, and other laboratory parameters including serum electrolytes, and plasma calcium and phosphorus levels were normal. Other laboratory values were as follows: urine norepinephrine (NE): 58 µg/24 h (normal: 20–81), urine epinephrine (E): 25 µg/24 h (normal: 2.0–22), urine normetanephrine: 709 µg/24 h (normal: 88–444), urine metanephrine: 2382 µg/24h (normal: 52–341), urine vanillylmandelic acid (VMA): 10 mg/24 h (normal: 1.8–6.7), urine dopamine: 197 µg/24 h (normal: 40–400), homovanillic acid (HVA): 3.36 mg/24 h (normal: 0.5–6.2) and urinary creatinine: 1.024 g/24 h. Serum basal cortisol was normal on the first day in the morning (16.2 µg/dl at 8:00), and diurnal cortisol variation revealed an AM cortisol of 11 µg/dl with a PM cortisol (at midnight) of 1.84 µg/dl in another day while ACTH level was 13 pg/ml (IRMA, normal range: 9.0–52 pg/ml). DHEAS was suppressed (<15 µg/dl; normal: 80–340 µg/dl). UFC was 69 µg/24h (N<60 µg/24h). A single-dose 1-mg overnight DST demonstrated a decrease in AM cortisol from 11.0 to 2.67 µg/dl. A low-dose 2-mg DST demonstrated a decrease in AM cortisol from 11.0 to 2.71 µg/dl and urinary UFC was 26 µg/day (normal<20 µg/day). A single-dose 8-mg overnight DST demonstrated a decrease in AM cortisol from 11.0 to 1.47 µg/dl. Plasma aldosterone concentration (PAC) was <0.7 ng/dl (normal: 7–30) and plasma renin level was 5.50 pg/ml (N: 5.41–34.53) during supine position. The results of other endocrine tests, including intact parathyroid hormone (iPTH) and thyroid hormones, were within normal ranges.

Abdominal computed tomography (CT) showed a well-demarcated, homogeneous, hypodense right adrenal solid mass (3.5×3.0 cm). In unenhanced CT scan, density of mass was 38 Hounsfield unit (HU), consistent with a

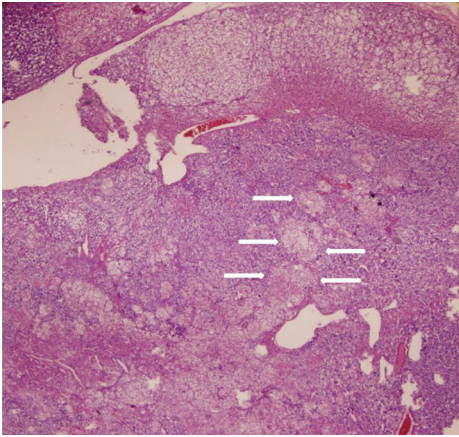


Figure 2. (A) Adrenal cortex hyperplasia (top) adjacent to pheochromocytoma (bottom) with pronounced cortical cell infiltration (arrows) in corticomedullary mixt adrenal tumor are seen (hematoxylin and eosin staining, original magnification:40).

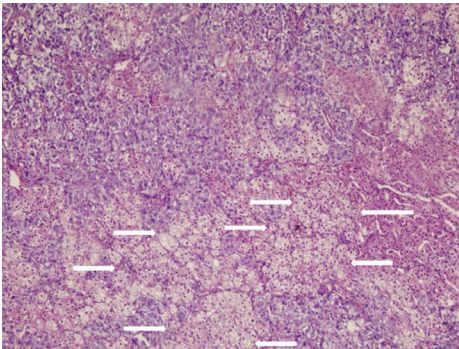


Figure 2. (B) Adrenocortical cell groups (arrows) embedded within pheochromocytoma (hematoxylin and eosin staining, original magnification:100).

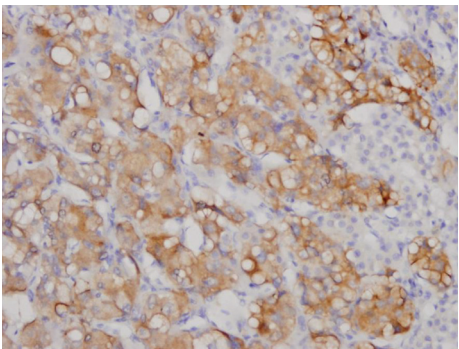


Figure 2. (C) Pheochromocytoma cells were positive for synaptophysin (immunohistochemical staining, original magnification:200).

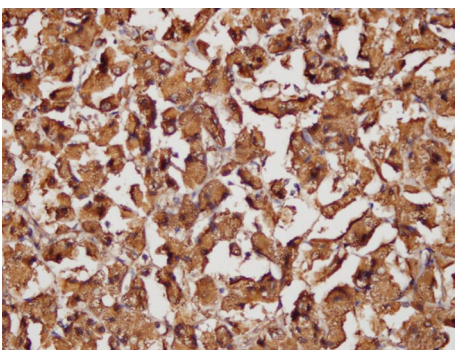


Figure 2. (D) Pheochromocytoma cells were positive for chromogranin A (immunohistochemical staining, original magnification:200).

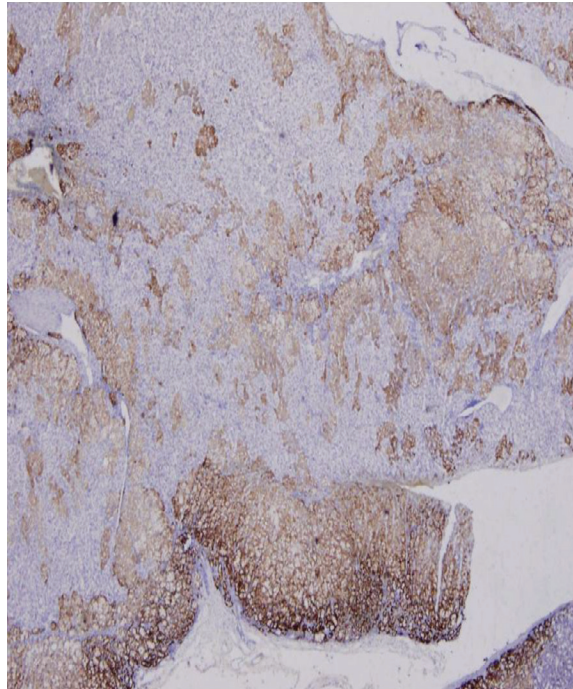


Figure 2. (E) Adrenal cortical cells were positive for melan-A (immunohistochemical staining, original magnification:40).

nonadenomatous mass. There were no features suggesting the invasion of surrounding structures, or enlarged lymph nodes. On T1-weighted abdominal magnetic resonance imaging (MRI), the tumor was visualized as a heterogeneous mass (3.5×3.0×2.5 cm) with a low signal intensity (hypointense) below that of the liver, located in the right adrenal gland (Figure 1A). T2-weighted MRI revealed a heterogeneous slightly hyperintense mass measuring 3.5×3.0×2.5 cm, located in right adrenal gland (Figure 1B). Out-of-phase MRI did not show significant signal loss in the lesion when compared with in-phase MRI (Figure 1C). Characteristics on MRI were not in favor of the diagnosis of adrenocortical adenoma. Left adrenal gland on imaging procedures was normal. A ¹³¹Iodine-metaiodobenzylguanidine (¹³¹I-MIBG) scan could not be performed.

From these findings, a diagnosis of right adrenal PHEO associated with SCS (since baseline plasma ACTH level is the lower limit of normal ranges, low baseline serum DHEAS level, slightly high UFC levels, nonsuppressible serum cortisol and UFC levels in DST) was made. Following the administration of adequate α -receptor blocking agents with phenoxybenzamine 80 mg/d, a β -adrenoceptor blocker (propranolol, 80 mg/d) was added to the therapy. Right adrenalectomy was performed by the transabdominal route under general anesthesia. The tumor was removed uneventfully. There were no hypotensive/hypertensive and/or hypoglycemia attacks during surgery. Also, as she had SCS, steroid replacement therapy (methyl prednisolone) was commenced on the day before surgery and tapered off gradually over 2 weeks. The resected right adrenal gland was 28.9 g

A CLINICALLY SILENT PHEOCHROMOCYTOMA COMBINED WITH SUBCLINICAL CUSHING'S SYNDROME IN THE SAME ADRENAL GLAND: A CASE REPORT AND REVIEW OF LITERATURE

Table. Summary of the data retrieved from the literature regarding clinical and biochemical characteristics of previously presented cases compared to the present one.

Case no	Study	Date of published case	Age (years)	Sex	Size (cm)	Symptoms	Hypertension	CS features	Hyperglycemia	Biochemical autonomous non-ACTH-dependent hypercortisolism	Biochemical PHEO	ACTH (pg/ml)
1	Finkenstedt <i>et al.</i>	1999	29	F	4	Yes	Yes	Yes mild	Yes	Yes	Yes	1.6
2	Erem <i>et al.</i>	2005	52	F	4	Yes	Yes	No	No	Yes	Yes	<5
3	Kastelan <i>et al.</i>	2007	43	F	1.9	Yes	No	No	No	Yes	Yes	8
4	Hwang <i>et al.</i>	2007	51	F	4.2	Yes	Yes	No	Yes	Yes	Yes	20.5
5	Yaylali <i>et al.</i>	2008	64	M	6	Yes mild	No	No	Yes	Yes	Yes	18.1
6	Alexandraki <i>et al.</i>	2009	66	F	4	No	Occasionally, mild	No	No	No	No	9.1
7	Kimura <i>et al.</i>	2009	54	F	5.3	Yes mild	Yes, mild	No	Yes	Yes	Yes	8
8	Takizawa <i>et al.</i>	2011	78	M	6	Yes	Yes	No	Yes	Yes	Yes	41.1
9	Current report	-	51	F	3.5	Yes	No	No	No	Yes	Yes	13

CS: Cushing's syndrome, ACTH: adrenocorticotrophic hormone, PHEO: pheochromocytoma

and contained a tumor measuring 5.0×4.5×2.5 cm in dimension. It was encapsulated. The cut surface of the tumor was solid with whitish grey color without evidence of hemorrhage or necrosis. Histopathological examination revealed that the tumor consisted of two different types of lesions: pheochromocytes and adrenocortical cells (Figure 2A) The pheochromocytoma component of the tumor contained nests of large, polygonal, and pleomorphic chief cells with granular basophilic cytoplasm and round to oval nuclei (Zellballen pattern) with adrenal cortical hyperplasia. Interestingly, adrenocortical cell groups embedded within PHEO (Figure 2B). Immunohistochemical studies were performed. The cells of PHEO were diffusely and strongly positive immunoreactivity for synaptophysin and chromogranin A (Figure 2C and 2D). The cells of adenocortical hyperplasia were strongly positive for melan-A (Figure 2E). ACTH immunochemistry revealed no positive cells in the tumor tissue. The specimen did not show any evidence of malignant degeneration histologically. Ki-67 index was <1%. The tumor was diagnosed as a adrenal PHEO associated with adrenocortical hyperplasia in the same adrenal gland. Postoperative course was uneventful, and no recurrence was detected at the 6 months follow-up visit. Urinary catecholamines and their metabolites was normal. Baseline serum cortisol was 12 µg/dl and ACTH was 19.6 pg/ml at 8:00 AM. A single-dose 1-mg overnight DST demonstrated a decrease in AM cortisol from 12.0 to 0.57 µg/dl.

DISCUSSION

In this report, we presented a case of clinically silent PHEO combined with SCS in the same adrenal gland in a 51-year old female patient. To our knowledge, our case is the first report described in the English literature.

The AIs may be adrenocortical adenomas and carcinomas, cysts, myelolipomas, pheochromocytomas, ganglioneuromas and adrenal metastases from other malignant tumors.¹). Approximately 5.0-6.5% of AIs are PHEOs, and 8% of the patients with a PHEO are completely asymptomatic.¹² Also, every AI should be screened for PHEO since it can account for up to 20% of cases.¹⁶ PHEO with SCS caused by corticomedullary mixed tumor of the adrenal gland are extremely rare. There have been 8 cases reported in the English medical literature.^{4,20,21,25-29} Table shows clinical and biochemical characteristics of these cases. In the present case (Table, case no. 9), PHEO and cortical hyperplasia coexisted in the same adrenal gland. The pathogenesis of mixed corticomedullary tumors is unknown. It is paradoxical that the two distinct cell populations are truly inseparable in a mixed tumor while adrenal cortex and medulla have different embryological origins and structure.^{30,31} One possible explanation is a genetic event in a stem cell, which gives rise to cells constituting the adrenal cortex and adrenal medulla.³⁰ Lee *et al.* speculated that an unidentified 'mutational event' in the intra-adrenal portal system leading to neoplastic changes of adrenocortical cells with cortical hypersecretion and may subsequently induce hyperplasia of the chromaffin cells via phenylethanolamine-N-methyltransferase system.³⁰

It has been reported that incidental PHEOs that are smaller than 1 cm in size have no clinical symptoms.³² Rarely, some large PHEOs do not show any clinical symptoms.^{12,15,33} On line of research from Mayo Clinic reveals that 15 of the 150 PHEO cases are diagnosed during abdominal CT taken for other reasons.³⁴ Our case showed no hypertension or paroxysmal hypertension attacks in her history. PE revealed no hypertension-related symptoms. ECG was normal, but there was left ventricle hypertrophy in borderline on echocardiography.

A biochemical diagnosis of a PHEO is made by measuring the 24-h urinary catecholamines and their metabolites. The values 2-3 times above the upper normal limit is considered to be diagnostic for a PHEO.^{11,12} Even though these patients are normotensive, most of them would have excess catecholamine secretion as measured by various biochemical tests.¹⁰ Despite having sustained elevated catecholamine concentration, normotension may be explained by desensitization or tolerance phenomenon.¹⁰ There is, in part, desensitization of the cardiovascular system to catecholamines in normotensive PHEO cases.³⁵ In the present case, 24-h urine metanephrine increased more than 7 times the normal and 24-h urine normetanephrine increased more than 1.5 times the normal.

Autonomous glucocorticoid production without specific symptoms and signs of CS is termed SCS.²⁸ SCS is the most frequent endocrine dysfunction detected in patients with adrenal mass incidentally found by radiologic imaging procedures for unrelated disease.³⁶ SCS is responsible for 5 to 20% of all AI cases.³⁶ It was also examined the diagnostic criteria of SCS in Japanese patients and observed that the most frequently found and reliable parameter was insufficient suppression of cortisol by low-dose DXM (100%).^{37,38} They defined this parameter as the essential item of the diagnostic criteria. A low baseline ACTH level, a blunted response of ACTH to CRH, a diminished circadian rhythm of cortisol and unilateral accumulation of radioisotope in tumors were also frequently observed. These items are considered as non-essential or minor indicators, but one or more indicators should be observed.³⁷⁻³⁹ Morioka *et al.* also reviewed the diagnostic parameters of SCS in Japanese patients and observed that the most frequently found parameter was plasma cortisol non-suppressible by low-dose DXM (90.9%), which was defined as a major or essential parameter.³⁷ Elevated UFC level was observed in only 44.9% of the cases evaluated, but this parameter was defined as a major item, because it was the definite sign of cortisol overproduction.³⁹ Other frequently found parameters were low baseline ACTH level (<10 pg/ml) (72.2%), a blunted response of ACTH to CRH (65%), suppressed DHEAS and the absence of the diurnal rhythm of cortisol (56.6%). Chiodini *et al.* proposed that cutoff value of serum cortisol after single-dose 1-mg overnight dexamethasone suppression >1.8 µg/dl associated with UFC>60 µg/24h.⁴⁰ In the present case, we preferred the above criteria. Also, our case fulfilled the two required criteria, which were incidental adrenal mass associated with autonomous cortisol overproduction and lack of clinical characteristics of CS. The endocrinological and pathological findings supported the autosecretion of cortisol. Also, ACTH immunochemistry revealed no positive cells in the tumor tissue. We therefore diagnosed this case as SCS.

The definitive treatment of choice for PHEO combined with SCS in the same adrenal gland is completed surgical resection when possible.²⁷⁻³⁰ With the development of

laparoscopic technique, adrenal tumor can be removed under laparoscopic procedure.^{29,30} Indeed, there is consensus that laparoscopic adrenalectomy is preferred over an open anterior operation for the resection of small benign adrenal tumors (less than 6 cm in diameter).^{2,41} Because, the rate of major complications from this procedure is very low. Also, the importance of expertise and the existence of a learning curve should be recognized.² Therefore, although laparoscopic adrenalectomy is the gold standard surgical treatment for a small sized-tumor, we preferred traditional open adrenalectomy as we had not an expertise for this surgery in our hospital. Clinically silent PHEOs might not be biologically silent, and there may be risks of surgical complications, including hypertensive and hypotensive crises.¹¹ Patients with PHEO regardless of whether it is clinically silent, should be treated the same as those with symptomatic disease.^{1,10,11} The acute and chronic effects of increased plasma catecholamines should be reversed prior to the surgical excision of the tumor. Combined α - and β -adrenergic blockades are required preoperatively to control high blood pressure and to prevent intraoperative hypertensive crises.¹ An α -adrenergic blockade (e.g., phenoxybenzamine or doxazosin) should be started at least 7 days preoperatively to allow for expansion of the contracted blood volume. A liberal salt diet is advised during the preoperative period. Once adequate α -adrenergic blockade is achieved, β -adrenergic blockade (e.g., propranolol or labetalol) is initiated (e.g., at least 3 days preoperatively). Moreover, SCS patients should receive perioperative glucocorticoid replacement therapy because they are at risk for hypoadrenalism after removal of the functioning mass. They should be monitored for subsequent hypothalamic-pituitary-adrenal axis recovery and clinical improvement.⁴² Prognosis of completely resected adrenal PHEO combined with SCS is excellent without further therapies.^{4,20,21,25-29} The recurrence rate for adrenal PHEO combined with SCS is near zero. However, life-long clinical and biochemical follow-up patients with adrenal PHEO combined with SCS is essential.

In conclusion, all AIs should be investigated for catecholamine and glucocorticoid hypersecretion. PHEO combined with SCS in the same adrenal gland is a rare entity. In our patient, we found an incidental adrenal mass. To our knowledge, the case is the first report of a clinically silent PHEO combined with SCS in the same adrenal gland. Preoperative diagnosis of these combined tumors is difficult. Its hormonal activity and imaging characteristics are frequently very similar to those of other adrenal tumors, especially pure PHEO. Therefore, careful evaluation by endocrine tests and multiple imaging procedures needs for provide a differential diagnosis. However, definitive diagnosis is established by histological and immunohistochemical studies.

*The authors declare that there are no conflicts of interest.



**A CLINICALLY SILENT
PHEOCHROMOCYTOMA
COMBINED WITH
SUBCLINICAL CUSHING'S
SYNDROME IN THE
SAME ADRENAL GLAND:
A CASE REPORT AND
REVIEW OF LITERATURE**

REFERENCES

1. Terzolo M, Bovio S, Pia A, Reimondo G, Angeli A. Management of adrenal incidentaloma. *Best Pract Res Clin Endocrinol Metab* 2009; 23: 233-243.
2. Terzolo M, Stigliano A, Chiodini I, et al. Italian Association of Clinical Endocrinologists. AME position statement on adrenal incidentaloma. *Eur J Endocrinol* 2011; 164: 851-870.
3. Barzon L, Sonino N, Fallo F, Palu G, Boscaro M. Prevalence and natural history of adrenal incidentalomas. *Eur J Endocrinol* 2003; 149: 273-285.
4. Hwang WR, Ma WY, Tso AL, et al. Pheochromocytoma and adrenocortical adenoma in the same gland. *J Chin Med Assoc* 2007; 70: 289-293.
5. Mantero F, Terzolo M, Arnaldi G, et al, Giovagnetti M, Opocher G, Angeli A. A survey on adrenal incidentaloma in Italy. Study Group on Adrenal Tumors of the Italian Society of Endocrinology. *J Clin Endocrinol Metab* 2000; 85: 637-644.
6. Erem C, Kocak M, Onder Ersoz H, Ersoz S, Yucel Y. Epinephrine-secreting cystic pheochromocytoma presenting with an incidentaladrena mass: a case report and a review of the literature. *Endocrine* 2005; 28: 225-230.
7. Adler JT, Meyer-Rochow GY, Chen H, et al. Pheochromocytoma: current approaches and future directions. *Oncologist* 2008; 13: 779-793.
8. Reisch N, Peczkowska M, Januszewicz A, Neumann HP. Pheochromocytoma: presentation, diagnosis and treatment. *J Hypertens* 2006; 24: 2331-2339.
9. Shao Y, Chen R, Shen ZJ, et al. Preoperative alpha blockade for normotensive pheochromocytoma: is it necessary? *J Hypertens* 2011; 29: 2429-2432.
10. Agarwal A, Gupta S, Mishra AK, Singh N, Mishra SK. Normotensive pheochromocytoma: institutional experience. *World J Surg* 2005; 29: 1185-1188.
11. Shen SJ, Cheng HM, Chiu AW, Chou CW, Chen JY. Perioperative hypertensive crisis in clinically silent pheochromocytomas: report of four cases. *Chang Gung Med J* 2005; 28: 44-50.
12. Kota SK, Kota SK, Panda S, Modi KD. Pheochromocytoma: an uncommon presentation of an asymptomatic and biochemically silent adrenal incidentaloma. *Malays J Med Sci* 2012; 19: 86-91.
13. Li C, Chen Y, Wang W, Teng L. A case of clinically silent giant right pheochromocytoma and review of literature. *Can Urol Assoc J* 2012; 6: E267-269.
14. Yoshida K, Sasaguri M, Kinoshita A, et al. A case of a clinically "silent" pheochromocytoma. *Jpn J Med* 1990; 29: 27-31.
15. Ozkaya M, Yuzbasioglu MF, Bulbuloglu E, et al. Incidental pheochromocytoma presenting with sublaboratory findings in asymptomatic surrenal masses: a case report. *Cases J* 2008; 1: 10.
16. Sukor N, Saidin R, Kamaruddin NA. Epinephrine-secreting pheochromocytoma in a normotensive woman with adrenal incidentaloma. *South Med J* 2007; 100: 73-74.
17. Suga K, Motoyama K, Hara A, et al. Tc-99m MIBG imaging in a huge clinically silent pheochromocytoma with cystic degeneration and massive hemorrhage. *Clin Nucl Med* 2000; 25: 796-800.
18. Verzeletti A, Amariti ML. Sudden death from an asymptomatic phaeochromocytoma: a case report. *J Forensic Leg Med* 2011; 18: 180-181.
19. Young WF Jr. Management approaches to adrenal incidentalomas. A view from Rochester, Minnesota. *Endocrinol Metab Clin North Am* 2000; 29: 159-185
20. Kastelan D, Ravic KG, Cacic M, et al. Severe postoperative hypoglycemia in a patient with pheochromocytoma and preclinical Cushing's syndrome. *Med Sci Monit* 2007; 13: CS34-37.
21. Erem C, Hacıhasanoğlu A, Ersoz HO, et al. Pheochromocytoma combined with preclinical Cushing's Syndrome in the same adrenal gland. *J Endocrinol Invest* 2005; 28: 561-565.
22. Chiodini I. Clinical review: Diagnosis and treatment of subclinical hypercortisolism. *J Clin Endocrinol Metab* 2011; 96: 1223-1236.
23. Terzolo M, Pia A, Reimondo G. Subclinical Cushing's syndrome: definition and management. *Clin Endocrinol (Oxf)* 2012; 76: 12-18.
24. Morelli V, Masserini B, Salcuni AS, et al. Subclinical hypercortisolism: correlation between biochemical diagnostic criteria and clinical aspects. *Clin Endocrinol (Oxf)* 2010; 73: 161-166.
25. Takizawa N, Muguruma K, Sasano H. Pheochromocytoma and subclinical Cushing's syndrome with focal adrenocortical hyperplasia. *Int J Urol* 2011; 18: 548-549.
26. Kimura T, Usui T, Inamoto S, et al. Image in endocrinology. Pheochromocytoma with subclinical Cushing's syndrome caused by corticomedullary mixed tumor of the adrenal gland. *J Clin Endocrinol Metab* 2009; 94: 746-747.
27. Alexandraki KI, Michail OP, Nonni A, et al. Corticomedullary mixed adrenal tumor: case report and literature review. *Endocr J* 2009; 56: 817-824.
28. Yaylali GF, Akin F, Bastemir M, Yaylali YT, Ozden A. Pheochromocytoma combined with subclinical Cushing's syndrome and pituitary microadenoma. *Clin Invest Med* 2008; 31: E176-181.
29. Finkenstedt G, Gasser RW, Höfle G, et al. Pheochromocytoma and sub-clinical Cushing's syndrome during pregnancy: diagnosis, medical pre-treatment and cure by laparoscopic unilateral adrenalectomy. *J Endocrinol Invest* 1999; 22: 551-557.
30. Lee P, Bradbury RA, Sy J, et al. Phaeochromocytoma and mixed corticomedullary tumour - a rare cause of Cushing's syndrome and labile hypertension in a primigravid woman postpartum. *Clin Endocrinol (Oxf)* 2008; 68: 492-494.
31. Wieneke JA, Thompson LD, Heffess CS. Corticomedullary mixed tumor of the adrenal gland. *Ann Diagn Pathol* 2001; 5: 304-308.
32. Blake MA, Krishnamoorthy SK, Boland GW, et al. Low-density pheochromocytoma on CT: a mimicker of adrenal adenoma. *AJR Am J Roentgenol* 2003; 181: 1663-1668.
33. Shin S, Tsujihata M, Miyake O, Itoh H, Itatani H. Asymptomatic pheochromocytoma: a report of three cases. *Hinyokika Kyo* 1994; 40: 1087-1091.
34. Kudva YC, Young WF, Thompson GB, et al. Adrenal incidentaloma: an important component of the clinical presentation spectrum of benign sporadic adrenal pheochromocytoma. *The Endocrinologist* 1999; 9: 77-81.
35. Tsujimoto G, Honda K, Hoffman BB, Hashimoto K. Desensitization of postjunctional alpha 1- and alpha 2-adrenergic receptor-mediated vasopressor responses in rat harboring pheochromocytoma. *Circ Res* 1987; 61: 86-98.
36. De Leo M, Cozzolino A, Colao A, Pivonello R. Subclinical Cushing's syndrome. *Best Pract Res Clin Endocrinol Metab* 2012; 26: 497-505.
37. Morioka M, Fujii T, Matsuki T, et al. Preclinical Cushing's syndrome: report of seven cases and a review of the literature. *Int J Urol* 2000; 7: 126-132.
38. Suda T. Adrenal preclinical Cushing's syndrome. *JMAJ* 2001; 45: 172-174.
39. Terzolo M, Osella G, Ali A, et al. Subclinical Cushing's syndrome in adrenal incidentaloma. *Clin Endocrinol (Oxf)* 1998; 48: 89-97.
40. Chiodini I, Tortolano M, Scillitani A, et al. Association of subclinical hypercortisolism with type 2 diabetes mellitus: a case-control study in hospitalized patients. *Eur J Endocrinol* 2005; 153: 837-844.
41. Erem C, Civan N, Fidan M, et al. Composite adrenal pheochromocytoma-ganglioneuroma in an adult patient. *Acta Endo (Buc)* 2014; 10: 140-149.
42. Inoue M, Ide H, Kurihara K, et al. Clinical Usefulness of Corticotropin Releasing Hormone Testing in Subclinical Cushing's Syndrome for Predicting Cortisol Replacement after Adrenalectomy. *Korean J Urol* 2012; 53: 414-418.