

THYROID ABSCESS IN A PATIENT WITH ACUTE LYMPHOBLASTIC LEUKEMIA DURING CHEMOTHERAPY INDUCED NEUTROPENIA

Gülstan Bahat, MD¹, Nilgün Erten, Assoc. Prof.¹, Bülent Saka, MD¹, Didem Akal, MD², Ali Çakır, MD³, Mehmet Akif Karan, Prof.¹, Cemil Taşcıoğlu, Prof.¹, Abdülkadir Kaysı, Prof.¹

¹ Department of Internal Medicine, Istanbul Medical School, Istanbul University

² Department of Clinical Microbiology and Infectious Disease, Istanbul Medical School, Istanbul University

³ Department of Internal Medicine, Radiology Section, Istanbul Medical School, Istanbul University

ABSTRACT

Febrile neutropenia is a commonly encountered complication during the treatment of hematological malignancies. Respiratory system, skin, gastrointestinal system and genitourinary system infections are the common causes of febrile neutropenia. The infection of thyroid gland is rarely seen even in neutropenic patients. Here, we describe a patient with acute lymphoblastic leukemia who was treated with intensive chemotherapy and developed suppurative thyroiditis during neutropenic period.

It is proposed that prior neutropenia and preceding cellulitis around the thyroid gland, which might be subsequent to oral mucosal damage induced by anticancer drugs, may play a role in the development of gland infection. Thyroid gland infection should be considered a potential complication of aggressive chemotherapy for leukemia.

• **Key Words:** Febrile neutropenia, thyroid abscess, suppurative thyroiditis, chemotherapy, acute leukemia. *Nobel Med 2006; 2 (2): 26-29*

ÖZET

AKUT LENFOBLASTİK LÖSEMİLİ BİR HASTADA KEMOTERAPİYE BAĞLI NÖTROPENİ DÖNEMİNDE GELİŞEN TİROİD ABSESİ

Febril nütropeni hematolojik malignitelerin tedavisi sırasında sık karşılaşılan bir komplikasyondur. Febril nütropenide en sık karşılaşılan infeksiyonlar solunum sistemi, deri, gastrointestinal sistem ve genitoüriner sistem infeksiyonlarıdır. Tiroid bezinin infeksiyonu ise nütropenik olgularda dahi nadir görülmektedir. Bu yazıda, akut lenfoblastik lösemi tanısıyla yoğun kemoterapi verilen bir hastada

nütropenik dönemde gelişmiş olan bir süpüratif tiroidit olgusu sunulmaktadır. Literatür kemoterapiyi takip eden dönemde gelişen tiroid infeksiyonları açısından gözden geçirilmiştir. Kemoterapi sonrasında gelişen nütropenin, oral mukoza hasarının ve takiben tiroid bölgesinde gelişen selülitin tiroid bezi infeksiyonu gelişiminde rolü olabileceği öne sürülmüştür. Tiroid infeksiyonu, yoğun kemoterapi tedavisinin nadir ancak potansiyel bir komplikasyonu olarak göz önünde bulundurulmalıdır.

• **Anahtar kelimeler:** Febril nütropeni, tiroid absesi, süpüratif tiroidit, kemoterapi, akut lösemi. *Nobel Med 2006; 2 (2): 26-29*

INTRODUCTION

Neutropenia and subsequent infection is an important and frequent morbidity and mortality factor in the chemotherapy given patients. In approximately half of the patients, despite the detailed clinical investigation, the infectious etiology cannot be identified.¹ In patients whom the infectious etiology is identified, the infection sites are respiratory system, skin, gastrointestinal system and genitourinary system according to decreased order of frequency. Thyroid is a rare site of infection in neutropenic patients. In this report, we present a case of suppurative thyroiditis and cellulitis in thyroid region in a patient with acute lymphoblastic leukemia (ALL) during the neutropenic period after chemotherapy. The medical literature is searched for thyroid abscess as a reason for febrile neutropenia and the possible mechanisms for the development of thyroid infection is discussed.

CASE

Common B ALL (with central nervous system involvement) was diagnosed in a 42 years old female patient in January 2002. She was given BFM phase 1 (daunorubicin 25 mg/m², vincristine 2 mg, methylprednisolone 48 mg/m², once a week, for 4 weeks) and thereafter fludarabine (30 mg/m², between days 2-6), cytosine arabinoside (1 gr/m², between days 1-6), intrathecal methotrexate (6 times) and cranial radiotherapy (10 days, 12 Gray/d). After the treatment, the first remission was achieved. Allogeneic stem cell transplantation was planned for her next treatment but it could not be performed since no appropriate donor had been found. Her treatment was planned as fludarabine and cytosine arabinoside once in 4-6 months. After a year, the first bone marrow relapse was diagnosed. With the treatment consisted of vincristine 2 mg/week, methylprednisolone 48 mg/d

(4 week), the second remission was achieved and fludarabine (30 mg/m², between days 2-6), cytosine arabinoside (1 gr/m² between days 1-6) treatment was started as consolidation treatment. At the second day of chemotherapy, on the neck, on the thyroid right lobe region, a painful swelling of 3x2 cm developed. There was no erythema or warmth of the skin on the lesion. The thyroid function tests were normal. By the neck ultrasonography (USG), an encapsulated cystic lesion of 33x20 mm compressing the thyroid right lobe was viewed (Figure 1). At the 11th day of chemotherapy, her temperature increased up to 39.5 °C. Her total leukocyte count was 150/mm³. It was diagnosed as febrile neutropenia and meropenem 3x1 g, amikacin 1x1 g treatment was started. At the second day of antibiotic treatment, an erythema appeared on the swelling at the neck and an induration zone of 5x3 cm involving the adjacent soft tissue developed (Figure 2). The neck USG was performed again and a high dense, hypochoic collection of 37x15x31 mm occupying the thyroid right lobe region was observed (Figure 3). At the thyroid scintigraphy, gland was larger, its activity distribution was heterogeneous and right lobe's upper part was hypoactive (Figure 4). The thyroid hormones were again in normal limits. Therefore, the suppuration of the extrathyroidal cyst was diagnosed. Since her fever sustained, vancomycin 4x500 mg treatment was added on the third day of antibiotic treatment. With this treatment, her temperature became normal and the induration on the neck disappeared completely. At the 8th day of vancomycin treatment, her temperature increased again and odynophagia complaint developed. Since there were vesicular lesions around her mouth and candidiasis in her oral cavity, acyclovir 5x800 mg and amphotericin B 60 mg were added to her therapy. At her upper gastrointestinal system endoscopy, diffuse ulcerations and nodular lesions were seen at the esophagus. Her temperature became normal

→ THYROID ABSCESS IN A PATIENT WITH ACUTE LYMPHOBLASTIC LEUKEMIA DURING CHEMOTHERAPY INDUCED NEUTROPENIA

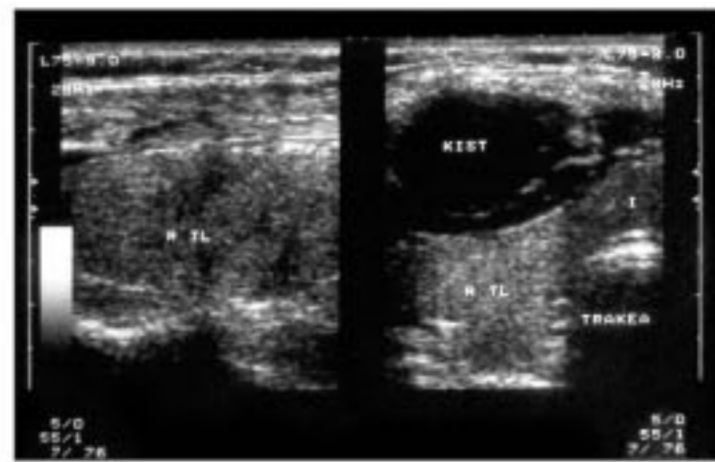


Figure 1. Thyroid USG reveals an encapsulated cystic lesion of 33x20 mm compressing the thyroid right lobe.

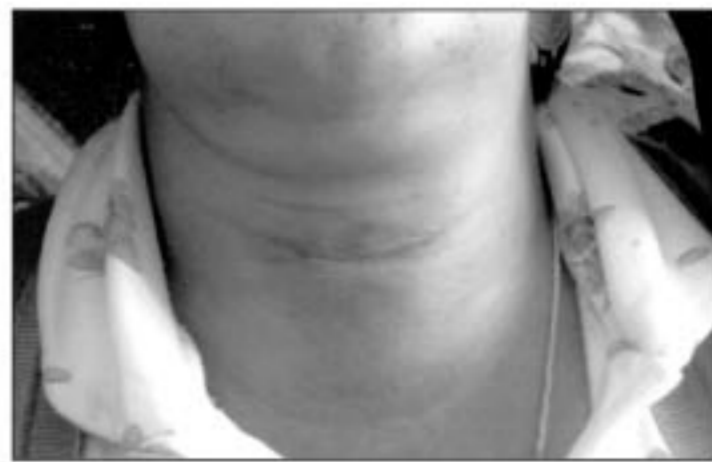

Figure 2. Erythema and an induration zone of 5x3 cm at the neck.

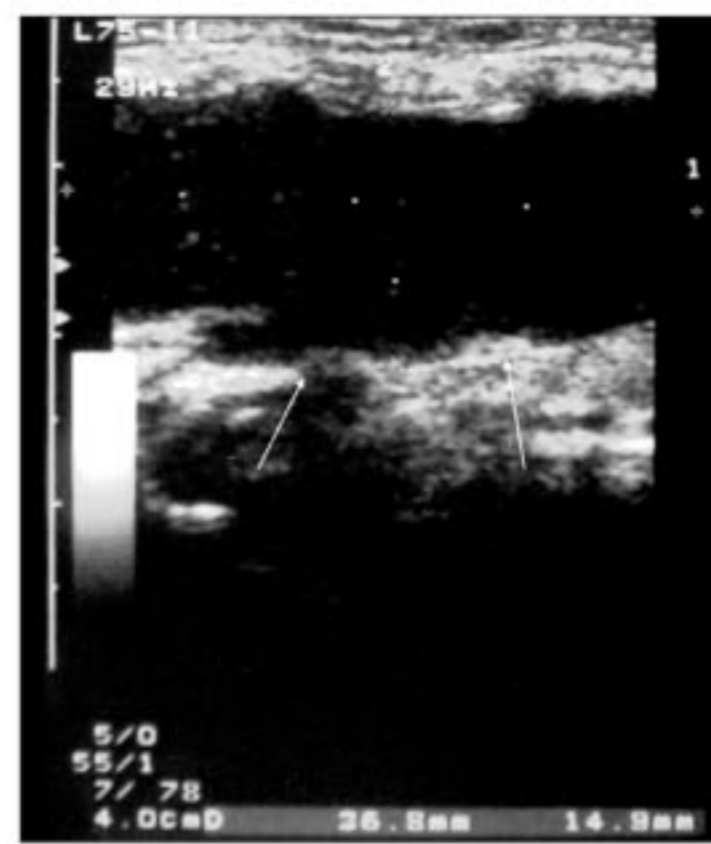

Figure 3. Neck USG: Hypoechoic collection of 37x15x31 mm occupying the thyroid right lobe region (suppuration of the extrathyroidal cyst).

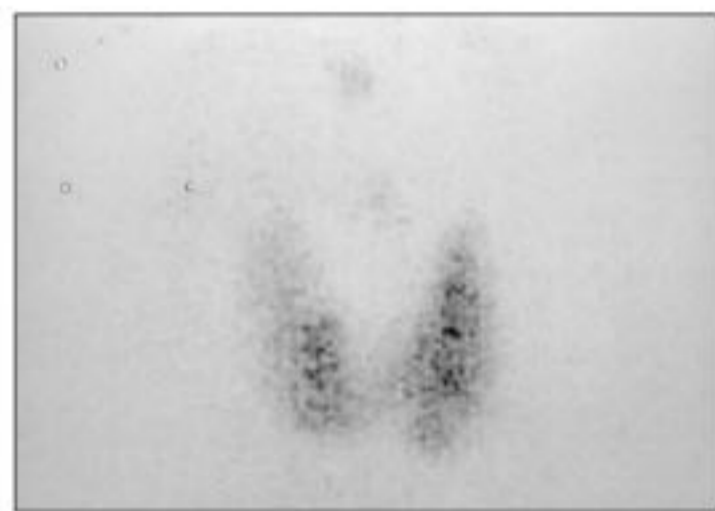

Figure 4. Thyroid scintigraphy: Thyroid gland was enlarged, its activity distribution was heterogeneous and right lobe's upper part was hypoactive

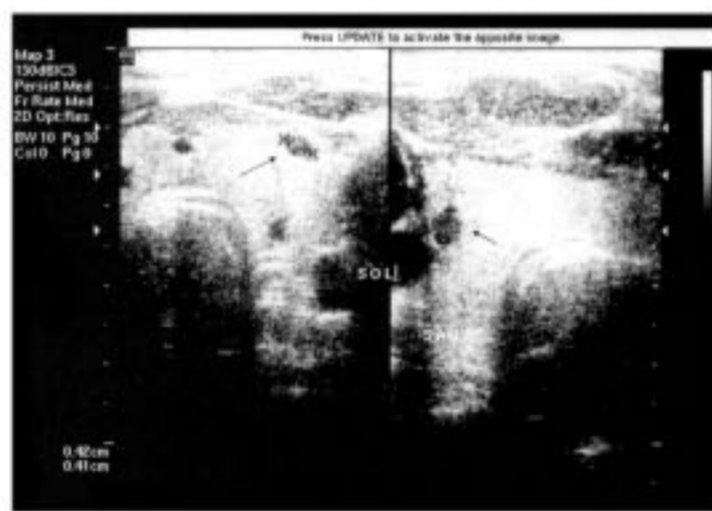


Figure 5a. Thyroid USG: Multiple anechoic cystic lesions compatible with abscess cavities in the thyroid gland

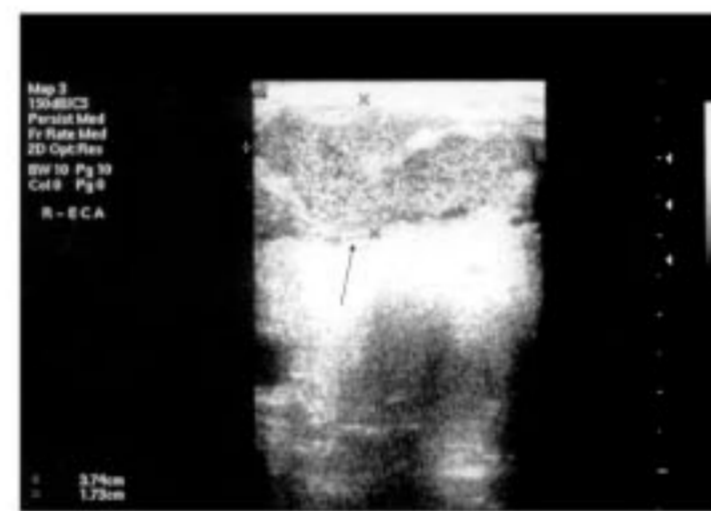


Figure 5b. Neck USG: Extrathyroidal abscess in the neighbourhood of the thyroid right lobe at the subcutaneous fatty tissue of the right side of the neck.

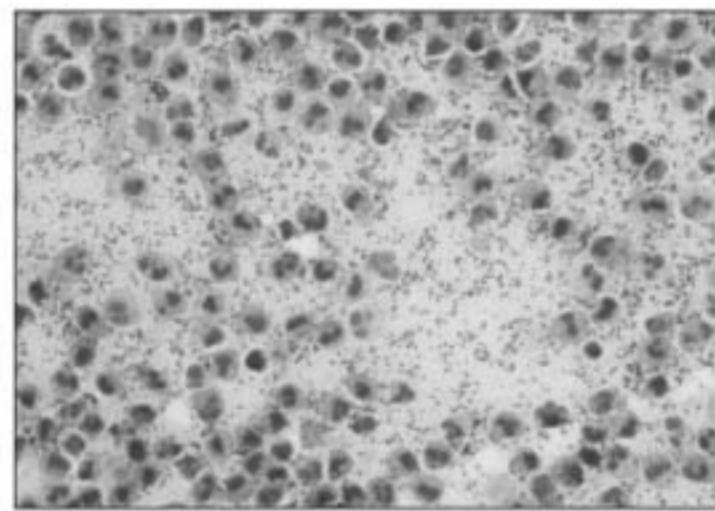


Figure 6. Gram staining of the pus obtained via fine needle aspiration: Gram positive cocci and many polymorphonuclear leukocytes.

again and her complaints disappeared with the treatment. Meropenem, vancomycin, acyclovir and amphotericin B treatments were stopped on the days 22, 18, 14, 21, respectively. The neck USG was performed again and at the USG, multiple anechoic cystic lesions compatible with abscess cavities in the thyroid gland and extrathyroidal

cultures remained negative (Figure 6). Drainage of the subcutaneous abscess was performed under local anesthesia. Her leukocyte count was found 21000/mm³. Since many blastic cells were seen in her subsequent peripheral blood smear, second relapse was diagnosed. Since relapse was noted during the fludarabine, cytosine arabinoside treatment and there was no allogeneic stem cell transplantation and curative chemotherapy possibility, vincristine 2 mg/week and methylprednisolone 32 mg/d (6 week) treatment was started for palliation and she was discharged from the hospital. She died at the 10th day of discharge because of hemorrhage due to thrombocytopenia.

DISCUSSION

In approximately half of the patients suffering from neutropenic fever, infectious etiology can not be identified despite the detailed clinical investigations.^{1,2} In the patients in whom the infectious etiology is identified, the infection site is respiratory system (35.7%), skin (13%), gastrointestinal system (7%), and genitourinary system (6%) in order of decreasing frequency.² Thyroid gland is a rare site of infection even in the neutropenic

patients.³ In the literature, there are few case reports of thyroid gland infection following chemotherapy. Imai et al. reported acute suppurative thyroiditis after intensive chemotherapy in two children suffering from acute myeloblastic leukemia.³ In those 2 patients, after chemotherapy, fever and pain had developed in thyroid region. In their laboratory work up, hyperthyroidism had been found and hypoechoic regions had been seen in their thyroid USG. Since they had been treated with antibiotics successfully, the bacterial infection had been thought as the etiological factor. One month later, after a transient hypothyroidism, the thyroid functions had become normal. Neutropenia and a possible prior cellulitis on the thyroid gland had been put forward to predispose to development of thyroiditis. In our patient, a prior extrathyroidal cyst developed and thereafter at the neutropenic period, suppuration of the extrathyroidal cyst and multiple abscess foci had been observed in the thyroid gland. Therefore possibly also in our patient, the cellulitis on the thyroid gland developed after chemotherapy induced oral mucosa damage, neutropenia and suppuration of the extrathyroidal cyst predisposed to abscess formation in the thyroid. In our patient, hyperthyroidism was not observed during her course. This might be explained by early control of thyroid abscesses via antibiotherapy. Also, in our case clinical success (disappearance of fever and induration) was achieved via antibiotherapy. However, the extrathyroidal abscess reduced in size but did not disappear completely and needed to be drained externally. In our patient, the bacterial etiology was confirmed by the Gram staining but not proven by the culture similar to the cases reported by Imai et al. The culture might have remained negative because of empirical early initiation of antibiotherapy owing wide antimicrobial spectra due to febrile neutropenia and performing the aspiration and culture after the clinical improvement. Since the culture of the pus was negative for any aerobic, anaerobic bacteria, *Candida* and the signs of the infection (e.g. systemic fever, erythema and induration on the neck) were disappeared by vancomycin treatment, methicillin-resistant *Staphylococcus* was thought to be the responsible microorganism.

Another thyroid abscess case following chemotherapy was reported by Da'as et al. and was observed during the course of febrile neutropenia and leukemia.⁴ In that case, dissimilar to other cases, not a bacterial but a fungal abscess (*Candida* abscess) had been diagnosed in the thyroid. However, no data of *Candida* infection had been found in the other organs or in the blood. Two other cases of fungal (*Candida*) thyroiditis were also presented in the literature in patients with leukemia where the fine needle aspiration aided the diagnosis.^{5,6} It is emphasized that acute suppurative thyroiditis of any origin is uncommon, but fungal infections of the gland are particularly rare.

On the other hand, also a case of suppurative salmonella thyroiditis is reported in an 82-year-old man with undiagnosed chronic lymphocytic leukemia (CLL) who presented with acute swelling of the thyroid goiter.⁷ Subsequent thyroid aspirate and blood culture yielded group B *Salmonella* thyroid abscess with septicemia. As a unique report, a case of suppurative thyroiditis is reported also in a bone marrow transplantation (BMT) patient. The patient was a 3-year-old boy of juvenile chronic myelomonocytic leukemia who underwent a second HLA matched bone marrow transplant from his sister.⁸ He developed hypothyroidism due to acute suppurative thyroiditis in the recovery phase of BMT which is an extremely rare complication of BMT.

As a conclusion, the case presented here represents a case of thyroid infection in chemotherapy given immunocompromised host. Because of the improvement of diagnostic techniques, intensive chemotherapy application and increased survival rate, this clinical situation might be seen as a complication of chemotherapy applied to leukemia patients. Therefore, thyroid abscess should be kept in mind as a rare source of infection in the immunocompromised host. Chemotherapy induced oral mucosa damage, neutropenia and subsequent cellulitis in the thyroid region might be the factors predisposing to thyroid gland infection.

İLETİŞİM İÇİN: Gülistan Bahat, MD, Istanbul University, Istanbul Medical School, Department of Internal Medicine Capa, 34390, Istanbul/Turkey, gbahat@turk@yahoo.com
GÖNDERİLDİĞİ TARİH: 06 / 06 / 2005 • KABUL TARİHİ: 13 / 10 / 2005

REFERENCES

- Meir HM, Balawi IA, Meer HM, et al. Fever and granulocytopenia in children with acute lymphoblastic leukemia under induction therapy. *Saudi Med J* 2001; 22: 423-427.
- Jagarlamudi R, Kumar L, Kochupillai V, et al. Infections in acute leukemia: an analysis of 240 febrile episodes. *Med Oncol* 2000; 17: 111-116.
- Imai C, Kakiyama T, Watanabe A, et al. Acute suppurative thyroiditis as a rare complication of aggressive chemotherapy in children with acute myelogenous leukemia. *Pediatr Hematol Oncol* 2002; 19: 247-253.
- Da'as N, Lossos IS, Yahalom V, et al. *Candida* abscess of the thyroid in a patient with acute lymphocytic leukemia. *Eur J Med Res* 1997; 2: 365-366.
- Gandhi RT, Tollin SR, Seely EW. Diagnosis of *Candida* thyroiditis by fine needle aspiration. *J Infect* 1994; 28: 77-81.
- Fernandez JF, Anaissie EJ, Vassilopoulou-Sellin R, Samaan NA. Acute fungal thyroiditis in a patient with acute myelogenous leukaemia. *J Intern Med* 1991; 230: 539-541.
- Dai MS, Chang H, Peng MY, Ho CL, Chao TY. Suppurative salmonella thyroiditis in a patient with chronic lymphocytic leukemia. *Ann Hematol* 2003; 82: 644-648.
- Poelman M, Benoit Y, Laureys G, Craen M, Leroy J. Acute suppurative thyroiditis complicating second allogeneic transplant for juvenile CML. *Bone Marrow Transplant* 1992; 10: 547-548.



THYROID ABSCESS IN A PATIENT WITH ACUTE LYMPHOBLASTIC LEUKEMIA DURING CHEMOTHERAPY INDUCED NEUTROPENIA